

Vision After *Early-Onset* Lesions of the Occipital Cortex: II. Physiological Studies

M.G. Knyazeva¹, P. Maeder², D.C. Kiper,^{1§} T. Deonna³, and G.M. Innocenti⁴

¹*Institut de Biologie Cellulaire et de Morphologie, University of Lausanne, Switzerland;*
²*Dept. of Radiology and* ³*Dept. of Pediatric Neurology, Centre Hospitalier Universitaire*
Vaudois (CHUV), Lausanne, Switzerland; ⁴*Division of Neuroanatomy and Brain*
Development, Dept. of Neuroscience, Karolinska Institutet, S-17177, Stockholm, Sweden.

SUMMARY

In one of two patients (MS and FJ) with bilateral, early-onset lesion of the primary visual cortex, Kiper et al. (2002) observed a considerable degree of functional recovery. To clarify the physiological mechanisms involved in the recovery, we used fMRI and quantitative EEG to study both patients. The fMRI investigations indicated that in both patients, isolated islands of the primary visual cortex are functioning, in the right hemisphere in MS and in the left in FJ. The functional recovery observed in MS roughly correlated with the functional maturation of interhemispheric connections and might reflect the role of cortico-cortical connectivity in visual perception. The functionality of interhemispheric connections was assessed by analyzing the changes in occipital inter-hemispheric coherence of EEG signals (ICoh) evoked by moving gratings. In the patient MS, this ICoh response was present at 7:11 y and was more mature at 9:2 y. In the more visually impaired patient, FJ, a consistent

increase in ICoh to visual stimuli could not be obtained, possibly because of the later occurrence of the lesion.

KEYWORDS

visual cortex, plasticity, development, lesion

INTRODUCTION

Cortical lesions sustained early in life are generally believed to be better compensated than are similar lesions sustained in adulthood (see for example, Cornwell et al., 1989; Webster et al., 1995; Moore et al., 1996; Payne et al., 1996; Payne & Lomber, 2001), but the nature of the reorganization underlying the spared function is not clear. At least three mechanisms can underlie the sparing of function after early cortical lesions.

- i) The first is the maintenance of transient thalamocortical projections conferring to the intact areas certain properties normally pertaining to the injured areas (Kalil et al., 1991; Guido et al., 1992; Illig et al., 2000).
- ii) The second is the reorganization of cortico-cortical connections (Caminiti & Innocenti, 1981; MacNail et al., 1996; Gao & Pallas, 1999; Pallas et al., 1999).

Reprint request to: Prof. G.M. Innocenti, Division of Neuroanatomy & Brain Development, Department of Neuroscience, Karolinska Institutet, S-17177, Stockholm, Sweden; e-mail: Giorgio.Innocenti@neuro.ki.se

[§]Present address: Institute of Neuroinformatics, University of ETH Zürich, Winterthurerstr. 190, 8057 Zürich, Switzerland

- iii) The third is the functional recovery of extrageniculate pathways to the extrastriate visual areas (Hovda & Villablanca, 1990).

Whether any mechanism above applies to early cortical lesions in children is unclear. In the companion article (Kiper et al., 2002), we described the cases of two subjects (MS and FJ) with early lesions of the visual areas as a consequence of bacterial meningitis. Both subjects have deficits in figure-background discrimination. In MS, who could be studied longitudinally, the deficits attenuated between the ages of 4.5 y and 8 y. In FJ, who is more impaired, the recovery, if any, was less.

To explain the residual deficits in these two patients and the remarkable, albeit exceptionally slow emergence of low level visual functions for MS, several physiological factors must be considered. First, it is important to know which parts of the visual cortex are still functional. We reasoned that the deficits could be attributed to the loss of most of the primary visual cortex, whose role in form perception and figure-ground segregation tasks has been stressed (see Discussion, Kiper et al., 2002). In contrast, the partial recovery in MS could be due to extrastriate areas progressively taking over the functions of the lost primary visual cortex. Yet, parts of the striate areas appeared to be preserved in both patients. We used fMRI to determine whether this preserved cortex was still functional, and/or whether the processing of visual information normally performed in areas V1 and V2 was now taking place in extrastriate areas.

In addition to assessing the functionality of different cortical regions, we also considered the possible involvement of the cortico-cortical connections, in particular those between areas of the two hemispheres. These connections link neurons that share the same preference for the orientation and the position of a visual stimulus,

and that represent the vertical meridian of the visual field. Thus, the cortico-cortical connections are presumably important for establishing the continuity between the visual representations in the two hemispheres and must be involved in tasks that require the binding of visual elements that appear in the two visual hemifields (discussed in Knyazeva et al., 1999). Furthermore, such connections were found to be affected by lesions sustained early in life, both in the somatosensory (Caminiti & Innocenti, 1981) and in the auditory cortex (Pallas et al., 1999). To assess the functionality of the cortico-cortical connections, we analyzed the coherence between the EEG signals recorded in the two hemispheres under visual stimulation. We recently proved the validity of this approach for testing cortico-cortical connectivity in animals and humans (Innocenti et al. 1999; Kiper et al. 1999; Knyazeva et al., 1999).

Our fMRI results indicate that in both patients, only the islands of the primary visual cortex are still functioning. On the other hand, in MS, visual-stimulus induced an increase in occipital inter-hemispheric EEG coherence in the beta-gamma band, a sign of cortico-cortical connectivity involvement in visual perception (Kiper et al., 1999; Knyazeva et al., 1999). This response matured late and could not be evoked in FJ, possibly because of its older age at the time of the lesion. A subset of our results has been published in abstract form (Kiper et al., 1998; Knyazeva & Innocenti, 2000; Knyazeva et al., 2000).

METHODS

Functional Magnetic Resonance Imagery (fMRI)

We used fMRI to assess the functionality of MS's and FJ's cortex and two controls, gender- and aged-matched to MS. The experiments were performed in accordance with local ethical require-

ments. The visual stimulus was a red and black checkerboard of 6×6 squares (28 by 28 deg) projected from a PC onto a translucent screen in front of the magnet and viewed by the subjects in a mirror. The contrast of the checkerboard was reversed every 125 ms. Subjects were instructed to fixate a white dot in the center of the screen. The control situation was rest in darkness, with eyes open. The experiments were performed with a 1.5T whole body system, using a head coil. An EPI single-shot sequence was used (matrix 128×128 , slice 5 mm thick with 1 mm gap, TE: 66 ms, FOV 25×25 cm). Sixty-two sets of seven (MS) to sixteen (FJ and controls), images parallel to the bicommissural plane covering the occipital and posterior parietal lobe were acquired during six ON/OFF epochs. Both preprocessing and data analysis were conducted on a Silicon Graphic Octane workstation with SPM99b (Wellcome Department of Cognitive Neurology, London, UK). Each subject's images were, at first, realigned to the first scan, calculating and applying translation and rotation parameters requisites to correct head movement during acquisition. All images were normalized to stereotaxic Talairach coordinates, as for adults, by matching each image to a MNI template (Montreal Neurological Institute) and resliced to $2 \times 2 \times 2$ mm voxel size using a sinc interpolation method. Afterwards, a smoothing procedure was applied to increase the signal-to-noise ratio, using an isotropic Gaussian kernel of 6 mm FWHM.

We performed the statistical analysis for each subject according to the General linear model as implemented in SPM99b; baseline drift across the imaging time series was attenuated with a high-pass filter. The contrast of interest (stimulus vs. rest) was estimated using a weighted square-wave function, and the respective hypotheses were tested with a *t*-statistic, generating a statistical parametrical map $SPM\{t\}$ of corresponding T values for each voxel. Regions significantly activated

were considered those surviving to a threshold of T value 3.19 ($p < 0.001$, uncorrected) and containing a cluster of, at least, 60 contiguous activated voxels. Because of the relative weaker BOLD signal in MS than in the controls, we used a threshold of T value 2.40 ($p < 0.01$, uncorrected).

Interhemispheric EEG coherence

To assay the functionality of MS's and FJ's visual callosal connections, we recorded their EEG under different conditions of visual stimulation. The technique and stimuli used are described in detail elsewhere (Knyazeva et al., 1999). In brief, the patient and the control subjects (three healthy girls age-matched to MS, and four young men from the adult control data published in Knyazeva et al. [1999] and in Knyazeva and Innocenti [2001] matching to FJ) viewed rectangular patches of black-and-white sinusoidal gratings presented on a uniform background of equal luminance. A small white square in the center of the screen served as a fixation point. We used three visual stimuli.

- *single iso-oriented* stimulus consisting of a patch of horizontal grating centered on the fixation point and drifting downwards.
- *bilateral orthogonally-oriented* stimulus consisting of two patches located symmetrically on the sides of the fixation point; one grating was oriented vertically and drifting downward, while the other was a horizontal grating drifting rightwards.
- *uniform gray screen* stimulus having the same space-averaged luminance as the other stimuli.

All gratings had a spatial frequency of 0.5 c/deg (a contrast of 50%) and drifted with a temporal frequency of 2 Hz. The stimuli were presented in randomized order for 2 sec each. The EEGs were recorded from O1, O2, PO3, PO4, P3, P4, PO7, PO8, T5, and T6 electrodes placed according to the extended 10-20 system (Nuwer et al., 1994).

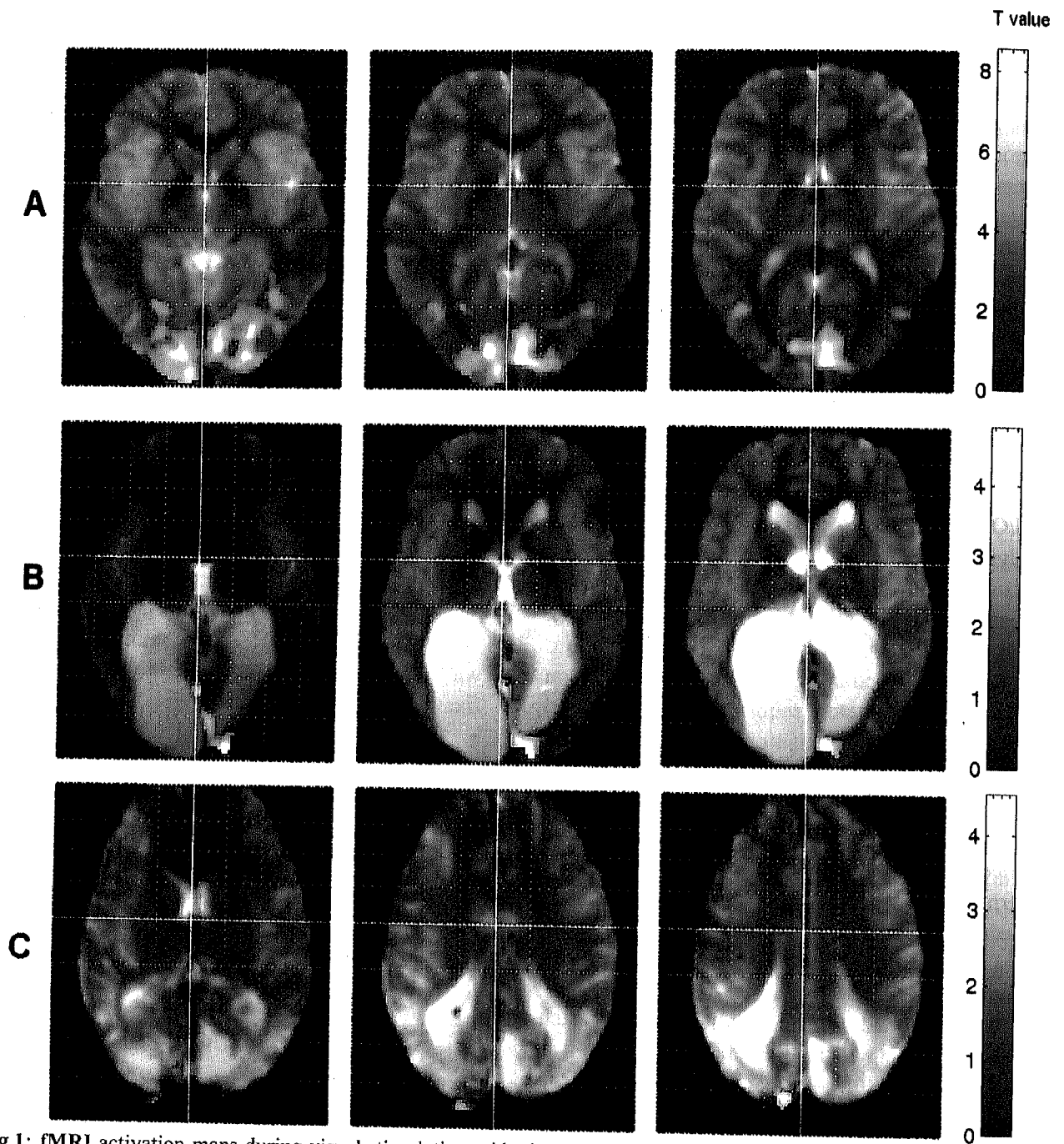


Fig 1: fMRI activation maps during visual stimulation with checkerboard displayed on axial slices A: control subject, 10:6 y ($Z=-6, 0, +6$ mm from AC-PC plan. Talairach coordinates, left: $-9, -99, -6$, middle: $-8, -93, 5$, right: $10, -93, 10$). B: patient MS, at 8:5 y ($Z=-18, -12, -6$ from AC-PC plan. Talairach coordinates, left: $16, -103, -18$, middle: $17, -102, -12$, right: $10, -77, -4$) C: patient FJ at 19:2y ($Z=8, 16, 24$ from AC-PC plane. Talairach coordinates, left: $-22, -97, 6$, middle: $-18, -102, 12$, right: $-14, -79, 16$). For the patients the images on the middle column correspond to the center of the activation cluster, those on the right and on the left are equidistantly spaced above and below the latter and correspond to the periphery of the activation cluster. In all subjects $p < 0.005$; $K 150$. Right side to the right in all cases.

Under these conditions, we recorded the EEG from MS at the ages of 6:10, 7:11, and 9:2 and that from FJ at the age of 18:8. The control girls were recorded at the ages of 7:8, 10:6 and the third one twice, at the ages of 6:7 and 8:8. Control men were 18 to 33 years old.

To obtain reliable data, we used several montage schemes. In adults, both ipsilateral earlobe referenced and bipolar EEG signals clearly demonstrated the dynamics of synchronization between the hemispheres (Knyazeva et al., 1999). Having in mind that in patients, EEG signals can be weaker or differently located than in control children or adults, we additionally analyzed standard bipolar derivations (O1-P3, O2-P4, O1-T5, O2-T6), and close bipolar derivations (O1-PO3, O2-PO4, O1-PO7, O2-PO8), more sensitive to the local cortical sources (Nunez et al., 1997).

For each condition, we processed 50 to 80 artifact-free epochs in each subject, except for 25 to 30 epochs in a control girl CH, at the age 6:7.

Coherence functions for symmetrical inter-hemispheric pairs of leads (ICoh) were calculated by averaging the primary spectral estimates (computed by Fast Fourier Transformation) over all epochs and smoothing the averages by Parsen's window. The coherence function (Coh) between two signals x and y at each frequency f was then calculated as:

$$\text{Coh}_{xy}(f) = |S_{xy}(f)| / (S_{xx}(f) * S_{yy}(f))$$

where $S_{xy}(f)$, $S_{xx}(f)$, $S_{yy}(f)$ are cross-spectrum and autospectrum estimates the x and y signals, respectively.

To contrast the ICoh levels associated with different stimulus conditions, we used the non-parametric Wilcoxon's test for both comparisons: single iso-oriented stimulus vs. bilateral orthogonally-oriented and vs. gray screen stimuli. The test was applied separately to the individual ICoh data from each electrode pair. The band means for

single epochs were used as input values to the statistics.

RESULTS

Functional magnetic resonance

The results of the fMRI experiment are shown in Fig. 1. The two control subjects (aged 7:8 and 10:6; Fig 1A) showed a pattern of activation similar to that of adults (Clarke et al., 2000). The primary visual cortex is strongly activated on both sides, together with bilateral activation in area V5/MT from the apparent motion of the stimulus.

In MS (Fig. 1B), most activity was taking place along the medial side of the right occipital lobe on both banks of the calcarine fissure. Little activation is seen in the left hemisphere, situated in the most anterior portion of the calcarine fissure. The findings suggest that islands of the cortex that have been preserved are functional. No activation was seen in extrastriate areas, including MT, which is surprising given that MS had little if any deficit in the perception of motion.

In FJ (Fig. 1C), the strongest activation was restricted to a cluster on the occipital pole of the left hemisphere.

EEG

The results of the EEG studies are shown in Fig. 2. In control subjects (Fig. 2C, left column), irrespective of age, we observed an ICoh response to the visual stimulation similar to that seen in adults (Knyazeva et al., 1999). The similarities are (a) the responsive frequency band, which was within the beta-gamma range (25–46 Hz), (b) the general topography of the response (occipitoparietal region), and (c) the relation between the stimulus type and the response (only the *single iso-oriented* stimulus increased ICoh). For the ipsilateral

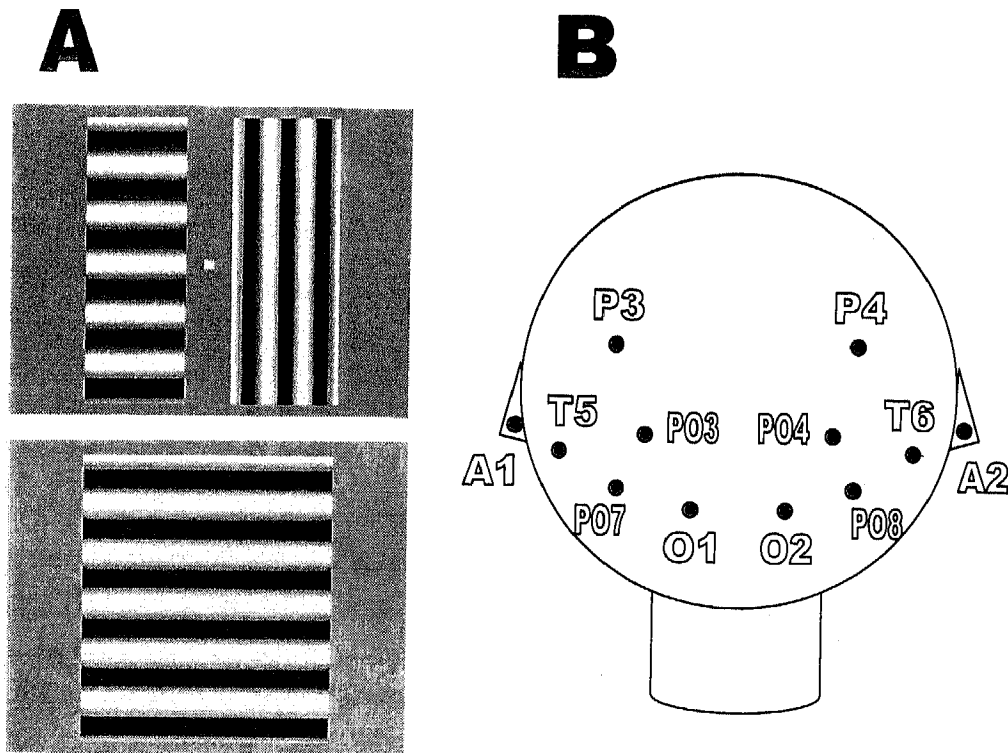


Fig. 2: Interhemispheric coherence (ICoh) spectra obtained under visual stimulation. (A) visual stimuli used; (B) scheme of positions of the occipital and parietal electrodes according to the International 10-20 system.

ear-referenced EEG signals, however, the interhemispheric synchronization to the *single iso-oriented* stimulus was weaker and less wide-spread in children than in adults. Indeed, ICoh increased compared to the different close stimulus, whereas we observed no significant response compared to the gray screen condition. Furthermore, ICoh increased in ear-referenced occipital derivation O1-A1/O2-A2 predominantly. A reliable and reproducible increase in ICoh was confirmed with close bipolar derivations with occipital location of electrodes O1-PO7/O2-PO8 and/or O1-PO3/O2-PO4.

The first EEG recording from MS at the age of 6:10 could not be analyzed because of artifacts. At the age of 7:11, for ear-referenced occipital EEG (O1-A1/O2-A2) we obtained no significant response to the *single iso-oriented* stimulus neither across the beta-gamma range 25-46 Hz responsive in

controls, nor in the sub-bands adjusted individually. We did obtain, however, a response from the parietal (P3-A1/P4-A2) and parieto-occipital (PO3-A1/PO4-A2) electrode sites (here and further see Table 1 for probability values). In bipolar derivations, the response was localized over occipito-parietal areas i.e., in the bipolar electrode pairs O1-P3/O2-P4 (not in Table 1), and the close bipolar PO3-PO7/PO4-PO8. Whether this was a normal response is unclear because none of these electrode pairs was responsive in the controls, nor in MS at age 9:2.

In the last EEG session at the age of 9:2, the ICoh increase to the *single iso-oriented* stimulus was seen over the parietal region (P3-A1/P4-A2), as at P 7:11, and also over intermediate points between parietal and occipital electrode locations (PO3-A1/PO4-A2). Unexpectedly the response was also observed over posterior temporal regions

C

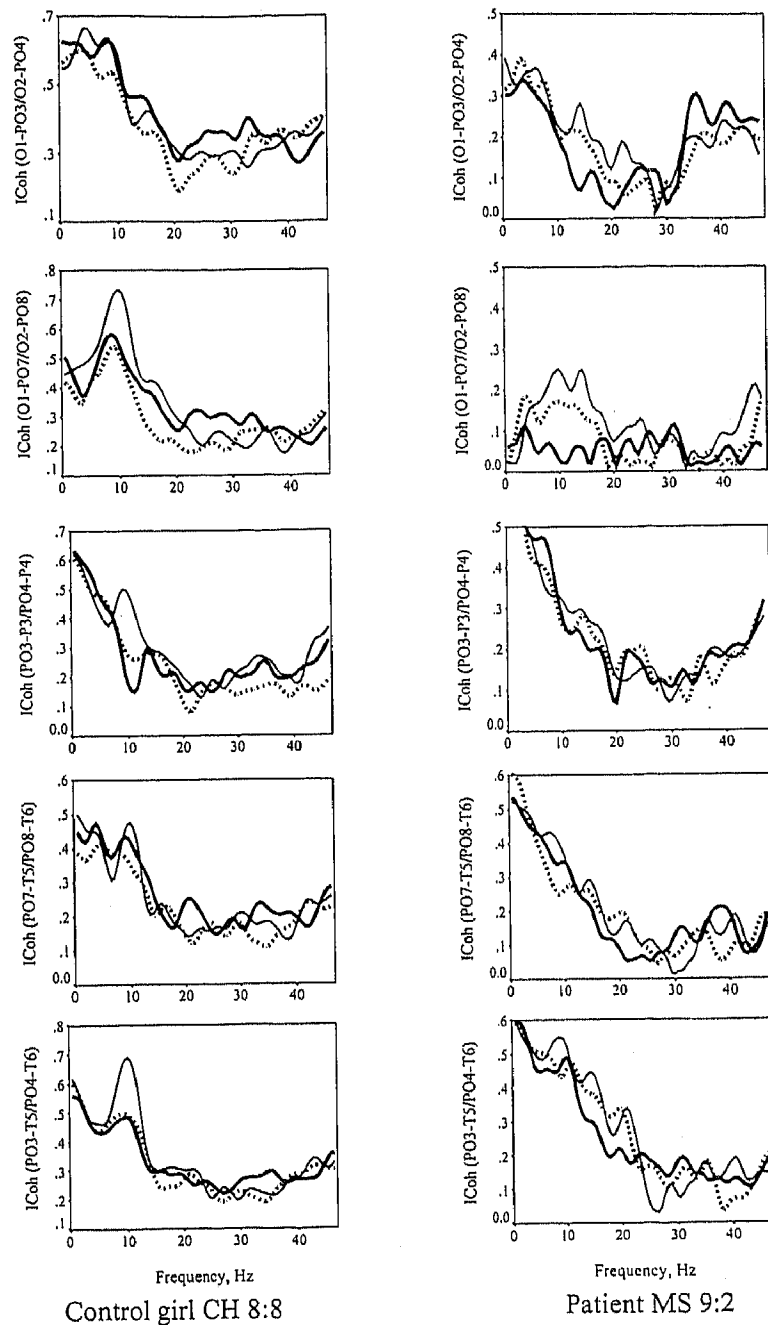


Fig. 2 (cont'd): (C) Interhemispheric coherence (ICoh) spectra obtained under visual stimulation. C) ICoh spectra obtained in the patient MS, and in the control girl. In the control subject, the *single iso-oriented* stimulus (thick line) increased ICoh compared to the gray screen (thin line) and the 'different' stimulus (dotted line), in the beta-gamma range. The clearest response was obtained from occipital electrode pairs O1-PO3/O2-PO4 and O1-PO7/O2-PO8. In MS, the significant response could be detected from extra-striate electrode locations only (see Table 2 for statistical assessment).

TABLE 1

Probability values for the interhemispheric coherence increase due to the *single iso-oriented* grating stimulus (SIG) compared to *bilateral orthogonally oriented* gratings (BOG) and *grey screen* (GS).

Subject/Age	Condition	Ipsilateral-ear-referenced derivations						Close bipolar derivations					
		O1-A1/ O2-A2	P3-A1/ P4-A2	PO3-A1/ PO4-A2	PO7-A1/ PO8-A2	T5-A1/ T6-A2		O1-PO3/ O2-PO4	O1-PO7/ O2-PO8	PO3-P3/ PO4-P4	PO3-T5/ PO4-T6	PO7-T5/ PO8-T6	PO3-PO7/ PO4-PO8
7:11	SIG > BOG	NS	0.003	0.018	NS	NS	NS	NS	NS	NS	NS	NS	0.007
MS	SIG > GS	NS	0.038*	NS	NS	NS	NS	NS	NS	NS	NS	NS	0.025
9:2	SIG > BOG	NS	0.039	0.060	NS	NS	0.081	NS	0.036*	NS	0.009*	0.076*	NS
	SIG > GS	NS	0.003	0.076	NS	0.0008	NS	NS	NS	NS	0.061*	NS	NS
CH 6:7	SIG > BOG	0.075	NS	NS	NS	NS	0.027	NS	NS	NS	NS	0.046	NS
	SIG > GS	NS	NS	NS	NS	NS	0.057	0.016	NS	0.044	NS	NS	NS
MT 7:8	SIG > BOG	0.003	NS	NS	0.072	NS	NS	0.016*	NS	NS	NS	NS	NS
	SIG > GS	NS	NS	NS	NS	NS	NS	NS	NS	NS	NS	NS	NS
CH 8:8	SIG > BOG	0.036	NS	NS	NS	NS	0.029	0.018	0.013	0.038	0.079	NS	NS
	SIG > GS	NS	NS	NS	NS	NS	0.016	0.053	0.084	NS	NS	NS	NS
VM 10:6	SIG > BOG	0.030	0.024	NS	0.097	0.083	0.019	NS	0.004*	NS	0.034	NS	NS
	SIG > GS	NS	NS	NS	NS	NS	NS	NS	NS	NS	NS	NS	NS

Note. MS is a patient. CH, MT and VM (the results from MT and VM see also in fMRI section) are control girls. the last one participated in the fMRI experiment.
 * Calculated for the individually adjusted frequency band within the beta-gamma range. All other values are given for the range of 25-46 Hz. NS stands for non-significant, i.e. $P > 0.1$. numbers in bold significant after Bonferroni correction. For further details see text.

(T5-A1/T6-A2). Unlike in normal adults and in the control girls, the ICoh response was not significant over the occipital region (O1-A1/O2-A2). The bipolar and close bipolar pairs of parietal and posterior temporal electrodes also responded to the *single iso-oriented stimulus* (see Table 1). The same electrode pairs were occasionally responsive in control children, as of age 6:7.

As a whole, the EEG coherence data suggest that in MS, the ICoh response emerged later than in the control girls and, probably, originated from the extra-striate cortex.

In FJ, ear-referenced EEG signals showed a broad band (25–46 Hz) increase to the single iso-oriented stimulus at a low level of statistical significance ($0.01 < P < 0.1$) extensively spread over occipital, parietal, and posterior temporal electrode locations. We failed to confirm, however, any ICoh response with bipolar or close bipolar derivations sensitive to local cortical sources, excluding the occipital cortex as a source of the ICoh changes observed.

DISCUSSION

Our study of MS and FJ indicates that their current visual impairment is the combined consequence of the loss of two components of visual perception, one that underwent minor or no compensation with age, the other which did, at least in MS.

The deficit in contrast sensitivity remained almost stable in MS over more than 4 y. It is tempting to ascribe this deficit to the probable partial degeneration of ganglion cells that follows the cortical lesion, as described in animals (see, for example, Cowey et al., 1982; Kisvarday et al., 1991). That a similar degeneration occurred in MS is suggested by the partial atrophy of the optic nerve, revealed by ophthalmological examination (Kiper et al., 2002).

In contrast, the analysis of visual functions that are dependent on cortical mechanisms provides a striking example of the visual system's adaptive developmental plasticity. Between 4 and 8 years of age, MS improved dramatically in both Vernier acuity and figure-background segregation tasks. The improvement in psychophysical performance was paralleled by changes in her daily visual behavior, as related by her school teachers and vision therapist and as evidenced by the quality of her spontaneous drawings. According to these sources, MS started to rely more and more on visual information to guide her behavior.

We assume, on the basis of anamnestic information, that FJ also partially recovered vision during his early childhood, in particular during his second year of age. Clearly, however, the functional recovery in FJ was less important than that of MS because, even despite his older, age he is much more severely impaired than MS.

Developmental plasticity and functional recovery

The condition of our two patients elicits the following two questions:

- i) What are the mechanisms responsible for the functional recovery in MS?
- ii) Why is the recovery in FJ less important?

Because the functional recovery took place several years after the occurrence of the lesions, the disappearance of acute local neuropathological phenomena as a cause for the recovery can be excluded.

We were expecting to find that the functional role of the visual areas had been taken over by other cortical areas. In animals, a particularly dramatic reorganization of the extrastriate areas has been demonstrated after early lesion of area 17. In kittens, a perinatal lesion of area 17 is followed by the maintenance of geniculo-cortical projection to the extrastriate area PMLS.

Consequently, this area maintains properties that are normally dependent on the input from area 17 or even acquires area 17-like properties (reviewed by Tong, 1988; Payne & Cornwell, 1994; Payne, 1999), albeit with some limits (Guido et al., 1992). This reorganization has been suggested to mediate functional sparing (Payne, 1999). A recent human fMRI study (Baseler et al., 1999) showed a reorganization of extrastriate visual areas after the lesion of a large portion of the primary visual cortex in an adult.

Therefore, we expected to see a strong activation of extrastriate areas when the patients were presented with a flickering checkerboard pattern, a stimulus that normally strongly activates the primary visual cortex. This was not the case. Instead, in both patients we found an activation of the remaining parts of the primary visual cortex and little or no activation elsewhere. The results suggest that functional recovery, particularly clear in MS, may not be due to the extrastriate areas acquiring the response properties and the perceptual role of the missing striate areas. Instead, functional maturation of the spared portion of the primary visual areas—or a more effective usage of the spared portions of the visual areas by the patient—might underlie functional recovery. Nevertheless, because we could not image the patient during the figure-background segregation tasks on which she showed functional recovery, the possibility remains that, in the absence of area 17, this task is indeed taken over, albeit incompletely, by extrastriate areas. More generally, the functional status of the extrastriate visual areas in this patient remains to be assessed with appropriate stimuli. The activation of extrastriate areas by moving gratings, presumably via the pulvinar, was reported in a case of bilateral perinatal lesion of the occipital cortex (Ptito et al., 1999).

The reorganization or delayed maturation of cortico-cortical connections, whose development plasticity is well known (Innocenti, 1991, 1995)

might have been a key factor in the recovery of function in MS. As discussed elsewhere (Kiper et al., 2002), cortico-cortical connections, including callosal connections, are probably involved in figure perception and figure-ground segregation. Reorganization of the cortico-cortical connections after early lesions has been demonstrated in cats (Caminiti & Innocenti, 1981; MacNeil et al., 1997), and was suggested as the likely mechanism underlying the cortical plasticity seen by Baseler et al. (1999). Thus, we tested the functionality of MS's cortico-cortical connections using EEG coherence analysis. In normal adults and in the control subjects reported here, ICoh increases for the *single iso-oriented grating* extending across the visual field, compared to *bilateral orthogonally-oriented gratings* or to *uniform grey screen*. The responsive derivations covered occipital and parietal areas. Previous recordings in our laboratory, using a Laplacian montage of electrodes, showed that the most probable source of the inter-hemispherically coherent signal is the occipital cortex in the vicinity of the O1/O2 electrodes (Knyazeva et al., unpublished).

In keeping with the absence of bilateral fMRI responses from the occipital poles, we failed to observe the stimulus-driven increase in inter-hemispheric EEG coherence from the occipital electrodes. However, at the age of 7:11, MS's parietal and parieto-occipital derivations showed the expected stimulus-dependent ICoh response. At the age of 9:8, the response was obtained from parietal, parieto-occipital, and, unexpectedly, from the parieto/occipital-temporal derivations. That the responses were obtained in close bipolar derivations suggests that they were of cortical origin. Such responses might reflect the activity in late maturing connections as they were not found in the controls before ages 8:8 and 10:6. In MS, an ICoh response also appeared in ear-referenced derivations recorded from the posterior temporal electrodes.

Thus, the improvement in MS's psychophysical performance and EEG responses with age suggests that they might be causally related to each other. Yet, the Vernier visual acuity improved between the ages of 4:5 and 6 y, and her performance in figure-ground segregation between 4:5 and 8 y. The EEG response was already present at 7:11, but increased markedly later, between the ages of 7:11 and 9:2 y. Possibly, a maturation of the cortico-cortical connections, sufficient to support the psychophysical amelioration, had occurred before it could be detected by the EEG method. In contrast, in FJ, whose recovery of visual perception was less than that in MS, no consistent changes in ICoh could be evoked with the visual stimuli. This result also speaks in favor of the hypothesis that functional recovery in MS might be, at least in part, related to the functional maturation of her cortico-cortical connections.

In conclusion, the fMRI and EEG results suggest that the functional recovery in MS may be due to the relative preservation of the right occipital areas, together with the maturation of callosal, and possibly other cortico-cortical connections, particularly those located at the junction between the parietal, temporal and occipital regions of the two hemispheres. To what extent the responses of the visual areas and the callosal connections are normal in this patient remains unclear and remain to be the focus of further studies.

Turning to the question of why FJ remained more severely impaired than MS, two concurrent causes come to mind.

The first is the different location of the lesion in the two cases. In particular, although the lesion of the occipital areas was bilateral, the right hemisphere was more affected in FJ and the left hemisphere in MS. Differences in the size of the lesion cannot be excluded either. Perusal of the literature indicates that right-hemisphere lesions are sufficient to cause severe apperceptive agnosia

(Warrington & James, 1988; Kartsounis & Warrington, 1991; De Renzi & Lucchinelli, 1993; Jambaqué et al., 1998), suggesting that the occipital region of the right hemisphere is specialized for figure integration and figure-ground discrimination. Although severe agnosia has also been reported in one case of bilateral occipital lesion, more severe on the left (Shelton et al., 1994), the more severe lesion of the right occipital lobe in FJ could explain his inferior functional recovery. A consequence of this conclusion would be that unilateral early lesions of the occipital lobe are not followed by functional compensation in the other hemisphere, unlike what is commonly believed to happen with language following early lesions of the left hemisphere. Interestingly, face processing also appears to be incompletely preserved after early lesions (Mancini et al., 1994). Of course it would be important to know which cortical regions MS and FJ use in those tasks in which MS appears to be less impaired.

The second cause for the worse functional recovery in FJ might be his older age at the time of the lesion. Indeed, at the time of the lesion he was about 8.5 months older than MS. As illustrated in Fig. 3, several crucial developmental events occur within this time window.

- i) The first is the developmental axonal elimination in the corpus callosum and, presumably, in other cortico-cortical connections, indirectly indicated by decreased size of the corpus callosum, (discussed in Innocenti, 1991).
- ii) The second is the synaptogenesis in the primary visual areas, which was at the onset at the time of MS' lesion and at its peak at the time of FJ's lesion.
- iii) The third is the onset of myelination in the telencephalic fibre tracts, notably the corpus callosum.

It is therefore tempting to suggest that the less complete recovery in FJ occurred because at the time of his lesion, crucial processes in the

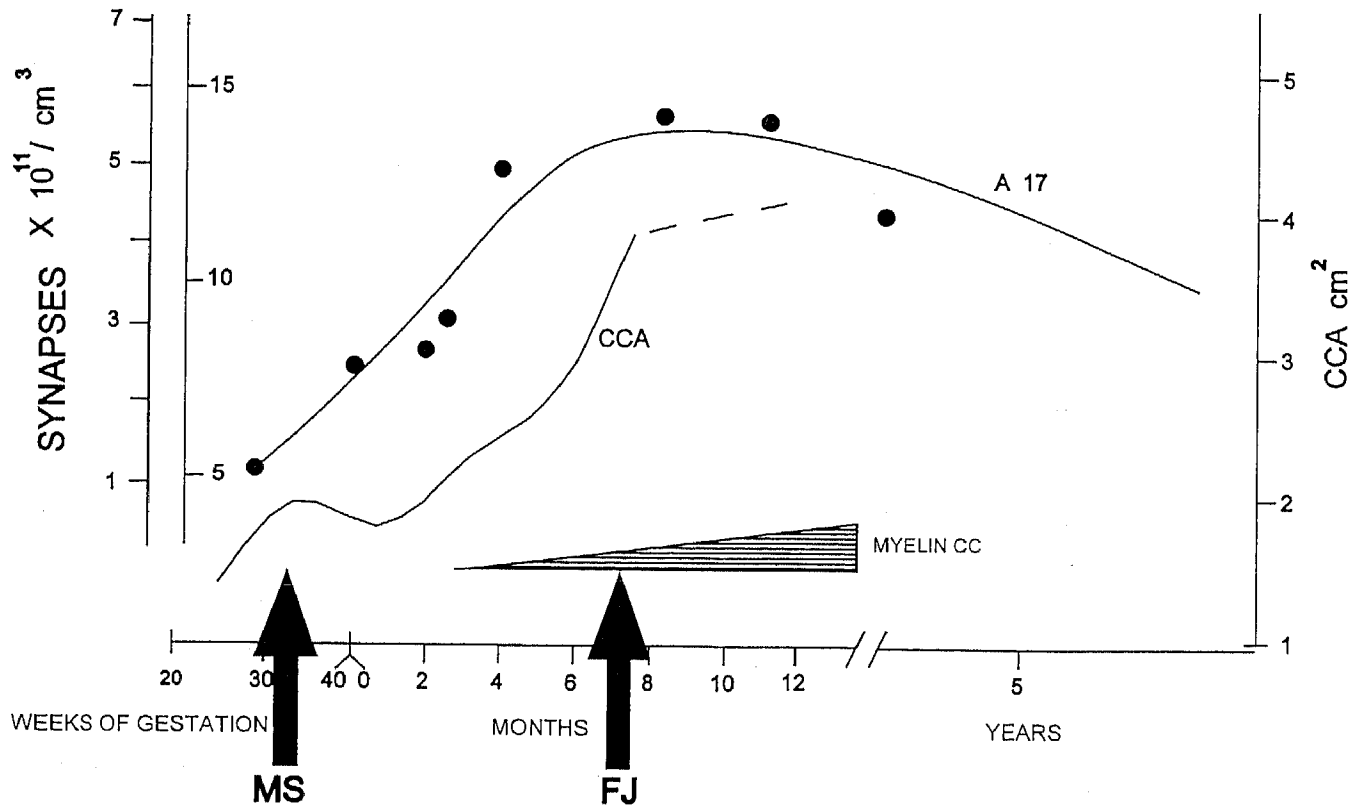


Fig. 3: Temporal relations of different aspects of cortical and callosal development in man, i.e., midsagittal corpus callosum area (CCA; continuous line), synaptogenesis in area 17 (dots), myelination of the corpus callosum (reprinted from Innocenti 1991).

development of cortico-cortical connections had already been completed and therefore could no longer be modified by epigenetic influences. This hypothesis can explain our failure in obtaining ICoh responses to visual stimulation in FJ, which we interpret as evidence of abnormal interhemispheric connectivity. It also explains the more severe perceptual impairment in FJ if the hypothesis that the functional recovery in MS might be due to maturation of her cortico-cortical connections, discussed above, is correct.

ACKNOWLEDGMENTS

This work was supported by Swiss National Science Foundation grant PNR38: n 4038-043990/1 and Swedish Medical Research Council grant n 12594. We would like to thank Dr. C.A. Hiroz for providing us with the perimetry results, Prof. P.A. Despland for allowing us to perform EEG recordings in his department. Special thanks go to Prof. C. Rivaz, who allowed us to perform the psychophysical experiments in the Institute for

Research in Ophthalmology (IRO), Sion, Switzerland, and to Mme. Matthis for her constant help.

REFERENCES

- Baseler HA, Morland AB, Wandell BA. 1999. Topographic organization of the human visual areas in the absence of input from the primary visual cortex. *J Neurosci* 19: 2619–2627.
- Bressoud R, Innocenti GM. 1999. Typology, early differentiation, and exuberant growth of a set of cortical axons. *J Comp Neurol* 406: 87–108.
- Caminiti R, Innocenti GM. 1981. The postnatal development of somatosensory callosal connections after partial lesions of somatosensory areas. *Exp Brain Res* 42: 53–62.
- Clarke S, Maeder P, Meuli P, Staub F, Bellmann A, Regli L, de Tribolet N. 2000. Interhemispheric transfer of visual motion information after a posterior callosal lesion: a neuropsychological and fMRI study. *Exp Brain Res* 132: 127–133.
- Cornwell P, Herbein S, Corso C, Eskew R, Warren JM, Payne B. 1989. Selective sparing after lesions of visual cortex in newborn kittens. *Behav Neurosci* 103:1176–1190.
- Cowey A, Henken DB, Perry VH. 1982. Effects on visual acuity of neonatal or adult tectal ablation in rats. *Exp Brain Res* 48: 149–152.
- De Renzi E, Lucchinelli F. 1993. The fuzzy boundaries of apperceptive agnosia. *Cortex* 29: 187–215.
- Gao W-J, Pallas SL. 1999. Cross-modal reorganization of horizontal connectivity in auditory cortex without altering thalamocortical projections. *J Neurosci* 19:7940–7950.
- Guido W, Spear P, Tong L. 1992. How complete is compensation in extrastriate cortex after visual cortex damage in kittens? *Exp Brain Res* 91: 455–466.
- Hovda DA, Villablanca JR. 1990. Sparing of visual field perception in neonatal but not adult cerebral hemispherectomized cats. Relationship with oxidative metabolism of the superior colliculus. *Behav Brain Res* 37: 119–132.
- Illig KR, Danilov YP, Ahmad A, Kim CBY, Spear PD. 2000. Functional plasticity in extrastriate visual cortex following neonatal visual cortex damage and monocular enucleation. *Brain Res* 882: 241–250.
- Innocenti GM. 1991. The development of projections from cerebral cortex. *Progr Sens Physiol* 12: 65–114.
- Innocenti GM. 1995. Exuberant development of connections and its possible permissive role in cortical evolution. *Trends Neurosci* 18: 397–402.
- Innocenti GM, Kiper DC, Knyazeva MG, Deonna TW. 1999. Nature and limits of cortical developmental plasticity in a child. *J Restorative Neurol Neurosci* 15: 219–227.
- Jambaqué I, Mottron L, Ponsot G, Chiron C. 1998. Autism and visual agnosia in a child with right occipital lobectomy. *J Neurol Neurosurg Psychiatry* 65: 555–560.
- Kalil RE, Tong LL, Spear PD. 1991. Thalamic projections to the lateral suprasylvian visual area in cats with neonatal or adult visual cortex damage. *J Comp Neurol.*; 314 : 512–25
- Kartsounis LD, Warrington EK. 1991. Failure of object recognition due to a breakdown of figure-ground discrimination in a patient with normal acuity. *Neuropsychologia* 29: 969–980.
- Kiper DC, Knyazeva MG, Tettoni L, Innocenti GM. 1999. Visual-stimulus-dependent changes in interhemispheric EEG coherence in ferrets. *J Neurophysiol* 82: 3082–3094.
- Kiper DC, Knyazeva MG, Maeder M, Maeder P, Despland PA, Innocenti GM. 1998. Central adaptations and spared visual capacities following cortical damage in children. *Eur J Neurosci Suppl* 10: 236.
- Kiper DC, Zesiger MG, Maeder P, Deonna T, Innocenti GM. 2002. Vision after early-onset lesions of the occipital cortex: I. Neuropsychological and psychophysical studies. *Neural Plasticity* 9: 1–25.
- Kisvarday ZF, Cowey A, Stoerig P, Somogyi P. 1991. Direct and indirect retinal input into degenerated dorsal lateral geniculate nucleus after striate cortical removal in monkey: implications for residual vision. *Exp Brain Res* 86: 271–292.
- Knyazeva MG, Innocenti GM. 2000. EEG correlates of functional connectivity in normal individuals, and following early cortical pathology. *Clin Neurophysiol Suppl* 111: S23.
- Knyazeva MG, Deonna T, Innocenti GM. 2000. Functional interhemispheric connectivity following early cortical pathology. *Eur J Neurosci Suppl* 12: 284.

- Knyazeva MG, Kiper DC, Vildavski VY, Despland PA, Maeder-Ingvar M, Innocenti GM. 1999. Visual-stimulus-dependent changes in interhemispheric EEG coherence in humans. *J Neurophysiol* 82: 3095–3107.
- MacNeil MA, Lomber SG, Payne BR. 1996. Rewiring of transcortical projections to middle suprasylvian cortex following early removal of cat areas 17 and 18. *Cereb Cortex* 6: 362–376.
- Mancini J, de Schonen S, Deruelle C, Massoulier A. 1994. Face recognition in children with early right or left brain damage. *Dev Med Child Neurol* 36: 156–166.
- Moore T, Rodman HR, Repp AB, Gross CG, Mezrich RS. 1996. Greater residual vision in monkeys after striate cortex damage in infancy. *J Neurophysiol* 76: 3928–3933.
- Nunez PL, Srinivasan R, Westdorp AF, Wijesinghe RS, Tucker DM, Silberstein RB, Cadush PJ. 1997. EEG coherency I: statistics, reference electrode, volume conduction, Laplacians, cortical imaging, and interpretation at multiple scales. *Electroencephalogr Clin Neurophysiol* 103: 499–515.
- Nuwer MR, Lehmann D, Lopes da Silva F, Matsuoka S, Sutherling W, Vibert JF. 1994. IFCN guidelines for topographic and frequency analysis of EEGs and EPs. Report of an IFCN Committee. *Electroencephalogr Clin Neurophysiol* 91: 1–5.
- Pallas SL, Littman T, Moore DR. 1999. Cross-modal reorganization of callosal connectivity without altering thalamocortical projections. *Proc Natl Acad Sci USA* 96: 8751–8756.
- Payne BR. 1999. System-wide repercussions and adaptive plasticity: the sequelae of immature visual cortex damage. *Rest Neurol Neurosci* 15: 81–106.
- Payne BR, Cornwell P. 1994. System-wide repercussions of damage to the immature visual cortex. *Trend Neurosci* 17: 126–30.
- Payne BR, Lomber SG, MacNeil MA, Cornwell P. 1996. Evidence for greater sight in blindsight following damage of primary visual cortex early in life. *Neuropsychologia* 34: 741–774.
- Payne BR and Lomber SG. 2001. Reconstructing functional systems after lesions of cerebral cortex. *Nature Rev Neurosci* 2: 911–919.
- Ptito M, Johannsen P, Faubert J, Gjedde A. 1999. Activation of human extrageniculate pathways after damage to area V1. *Neuroimage* 9: 97–107.
- Shelton PA, Bowers D, Duara R, Heilman KM. 1994. Apperceptive visual agnosia: A case study. *Brain Cogn* 25: 1–23.
- Tong L. 1988. Mechanisms of functional compensation in the posteromedial lateral suprasylvian visual cortex (PMLS) of cats with an early visual cortex lesion (areas 17, 18 and 19). In: Yew DI, So KF, Tsang DSC, eds, *Vision: Structure and Function*. Singapore: World Scientific; 419–442.
- Warrington E, James M. 1988. Visual apperceptive agnosia: a clinico-anatomical study of three cases. *Cortex* 24: 13–32.
- Webster MJ, Ungerleider LG, Bachevalier J. 1995. Development and plasticity of the neural circuitry underlying visual recognition memory. *Can J Physiol Pharmacol* 73: 1364–1371.