

Vision After *Early-Onset* Lesions of the Occipital Cortex: I. Neuropsychological and Psychophysical Studies

D.C. Kiper^{1§}, P. Zesiger², P. Maeder³, T. Deonna⁴ and G.M. Innocenti⁵

¹*Institut de Biologie Cellulaire et de Morphologie, University of Lausanne, Switzerland;*

²*Faculty of Psychology and Educational Science, University of Geneva, Switzerland;*

³*Dept. of Radiology and* ⁴*Dept. of Pediatric Neurology, Centre Hospitalier Universitaire Vaudois (CHUV), Lausanne, Switzerland;*

⁵*Division of Neuroanatomy and Brain Development, Department of Neuroscience, Karolinska Institutet, S-17177, Stockholm, Sweden*

SUMMARY

We analyzed the visual functions of two patients (MS, FJ) with bilateral lesion of the primary visual cortex, which occurred at gestational age 33 wk in MS and at postnatal month 7 in FJ. In both patients basic visual functions—visual acuity, contrast sensitivity, color, form, motion perception—are similarly preserved or modestly impaired. Functions requiring higher visual processing, particularly figure-ground segregation based on textural cues, are severely impaired. In MS, studied longitudinally, the deficits attenuated between the ages of 4.5 and 8 y, suggesting that the developing visual system can display a considerable degree of adaptive plasticity several years after the occurrence of a lesion. In FJ (age 18:9 to 20:6 y), who is more impaired, the recovery, if any, was less.

KEYWORDS

visual cortex, plasticity, development, lesion

Reprint request to: Prof. G.M. Innocenti, Division of Neuroanatomy & Brain Development, Department of Neuroscience, Karolinska Institutet, S-17177, Stockholm, Sweden;
e-mail: Giorgio.Innocenti@neuro.ki.se

[§]Present address: Institute of Neuroinformatics, University/ETH Zürich, Winterthurerstr. 190, 8057 Zürich, Switzerland.

INTRODUCTION

The consequences of visual cortex lesions in adults have been extensively studied in both humans and animals. In humans, cortical lesions result in permanent deficits, whose nature largely depends on the location and extent of the lesions. For example, selective deficits in the perception of color or motion result from lesions to the cortical areas involved in those aspects of visual perception (Covey, 1982; Marcar et al., 1997; Clarke et al., 1998). Most dramatically, primary visual cortex lesions create blind areas called scotomas in the visual field of adult human subjects (Weiskrantz, 1990; Zeki, 1993). Nevertheless, lesion-induced deficits in adults are by no means absolute. The recovery of function following cortical damage, an important aspect of cortical plasticity, is the current research focus of many laboratories. A partial reorganization of cortical sensory maps (Merzenich et al., 1984; Allard et al., 1991; Recanzone et al., 1993; Darian-Smith & Gilbert, 1994) might be the substrate for functional recovery in the adult brain (see also Safran & Landis, 1999 for references and discussion).

The consequences of cortical lesions sustained early in life are probably even more complex. Although early lesions are generally believed to be better compensated than are late lesions (the so-

called Kennard principle; see for example Moore et al., 1996, Payne et al., 1996), this principle has been challenged (Schneider, 1979). Indeed, the physiological and anatomical consequences of lesions sustained during development depend on factors like the size and location of the lesion and the age at onset of the lesion. In particular, the enhanced degeneration at a distance from the lesion (Covey et al., 1982; Perry & Covey, 1982; Kisvarday et al., 1997) and the formation of aberrant, maladaptive connections can seriously limit functional recovery after early lesions (Schneider, 1981). On the other hand, the developing cortex is characterized by impressive numbers of exuberant axonal branches and synapses (Innocenti, 1991, 1995; Bressoud & Innocenti, 1999) whose role in lesion-induced reorganization is not clear.

Recent experiments in cats showed that perinatal lesions of the primary visual cortex result in system-wide repercussions on neural circuitry that include the retina, thalamus, midbrain, and extrastriate cortex (reviewed in Payne & Cornwell, 1994; Payne, 1999). A dramatic plasticity of the developing nervous system has been demonstrated in hamsters and ferrets (Frost, 1986; Metin & Frost, 1989; Sur et al., 1990), in whom appropriately placed neonatal lesions can route information of one sensory modality into the circuitry of another sensory modality. The results suggest that early lesions induce a complex neuronal reorganization that might reduce, or even prevent, the emergence of deficits. Consistent with this view, an important visual field recovery was reported to occur in a patient with perinatal bilateral occipital lobe damage, some 24 y after the lesion (Ptito et al., 1999). Nevertheless, whether similar reorganization can be expected in animals and man and if it does, what the functional consequences might be is unclear.

Therefore, we studied two subjects with early lesions of the visual areas: MS, a little girl whose visual function we followed over several years,

and FJ, a young man with similar lesions that had occurred about 7.5 mo later than those in the girl. A comparison of these two patients revealed both similarities and differences in their conditions. The first appear to highlight the general consequences of the early lesions, whereas the second might be related to their different stages of brain maturation at the time of the insult.

In both patients, basic visual functions were only marginally impaired. In contrast, functions requiring higher-order visual processing, such as figure construction or figure-ground segregation based on textural cues, were severely impaired, although in MS they underwent dramatic recovery at an early age. A comparative analysis of these subjects, using neuropsychological and psychophysical measures and physiological investigations with fMRI and EEG, provide some insight into the possible mechanisms of recovery in MS (Knyazeva et al., 2002)¹.

SUBJECTS

Patient MS

Patient MS, born prematurely at 30 wk of gestation, suffered from bacterial meningitis at 5 weeks of age postpartum. The first brain ultrasonography (US) at 4 wk was normal; in particular showing no evidence of periventricular leucomalacia. Two subsequent US, 6 d and 18 d after the diagnosis of meningitis, showed an enlarged left posterior ventricle. The first MRI done at 3 y of age showed moderate hydrocephalus with massive enlargements of the occipital horns, no visible occipital cortex on the left, and a thin ribbon on the right. As Fig. 1 shows, most but not all the medial occipital cortex had either disappeared or was atrophied on both sides, including the calcarine sulci

¹A subset of our results has been published in abstract format Kiper et al., 1998; Innocenti et al., 1999; Knyazeva et al., 2000.

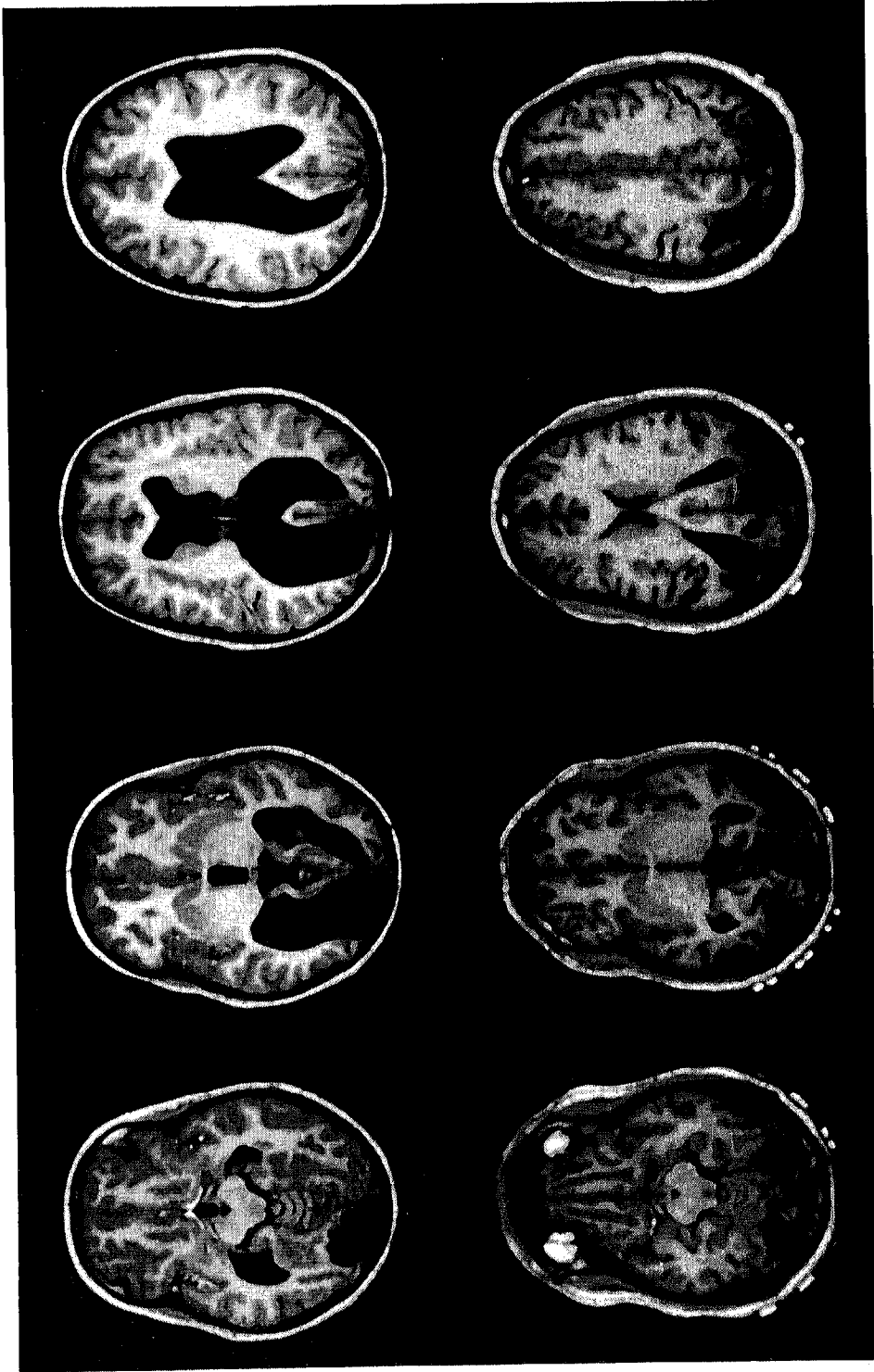


Fig. 1: Top: Representative examples of the MRI sections of MS's brain (at 8:4 y). Bottom: Representative MRI sections through FJ's (at 19:2 y). The second upper and lower sections, from the left are matched sections through the AC-PC plane, the other sections are identically spaced above and below this plane. Left hemisphere is to the left in all sections.

and the occipital pole, as far as the parieto-occipital sulcus, inclusive of much of Brodmann's areas 17 and 18 and part of area 19. Compared with the visual localization of Zilles and Clarke (1997), the lesion appears to correspond to much of areas V1, V2, and V3. V4, which is located in the collateral sulcus (Hasnain et al, 2001) might also be affected, particularly in the left hemisphere, where the lesion is more extensive.

Because of the MRI findings, MS was referred to the Pediatric Neurology Service at the age of 3 y and 5 mo (3:5). She presented as a girl with normal neurological and cognitive development. She walked at 16 mo and made sentences at 2 y. MS showed hardly any visual exploratory behavior, however, and little or no response to visual stimuli, symptoms usually associated with 'cortical blindness'. She had a mild esotropia, but no measurable refractive errors. The fundoscopic examination was normal. The diagnosis was hydrocephalus with destructive cortical lesion from meningitis.

At the age of 6:2, MS presented after two episodes of vomiting with impairment of consciousness. Her EEG showed right-sided occipital epileptic discharges that were present with eyes both open and closed and whose intensity decreased with visual attention. No changes in her visual deficits were noted before or after these episodes, which were diagnosed as partial complex epilepsy, secondary to her cortical pathology. She was not given antiepileptic therapy, and no subsequent seizures have occurred, although certain EEG abnormalities remained.

An analysis of MS's visual field was made at the ages of 7:6 and 8: 8 with similar results, albeit complicated by unstable fixation. Figure 2 shows that her residual visual field (7:6 y) was restricted to a 20 to 40 degree crescent in the pericentral superior hemifield. At the same age, uncorrected visual acuity was 2/60 in the right eye and 3/60 in the left eye. Further ophthalmologic examination at the age of 8:8 showed atrophy of the optic nerve,

which was noticeable ophthalmoscopically as an excavation of the optic disc. Tomographic analysis of the optic nerve showed a disk area of 2.39 mm² and a cup area of 0.852 mm² for the left eye, a disk area of 1.94 mm² and a cup area of 1.0 mm² for the right eye. The values are close to those reported by Jacobson et al. (1997) for children with periventricular leukomalacia associated with visual impairment. The relatively large size of the optic cup vs. that of the optic disk compared with normal (0.52 and 2.82 mm²) is, probably, a sign of retrograde degeneration of ganglion cells (Jacobson et al., 1997).

Patient FJ

Patient FJ was born 2 weeks before term by normal delivery. At 7 months of age, he was hospitalized with high fever and episthotonus. *Hemophilus influenzae* was identified in the blood and cerebrospinal fluid. The EEG showed spike-and-wave complexes in the parieto-occipital region of the right hemisphere. The CT scan revealed bilateral symmetric occipital hypodensities. He was treated with antibiotics and with antiepileptic medications that continued until 14 years of age. Three weeks later, the child showed hemiparesis on the right side and seemed blind. One month later, ophthalmologic examination revealed decreased visual acuity, divergent strabismus, and delay in optomotor development. Over the following year, the visual function seemed to improve. The child could follow the light but not small objects presented on the palm of the hand, an indication of bilateral visual impairment. The angle of strabismus varied between convergent and divergent. FJ walked at 15 to 16 months and developed language at a normal age. At 14 years of age, a neurological examination revealed a slight motor syndrome on the right side, difficulties at identifying complex objects, and mild mental retardation.

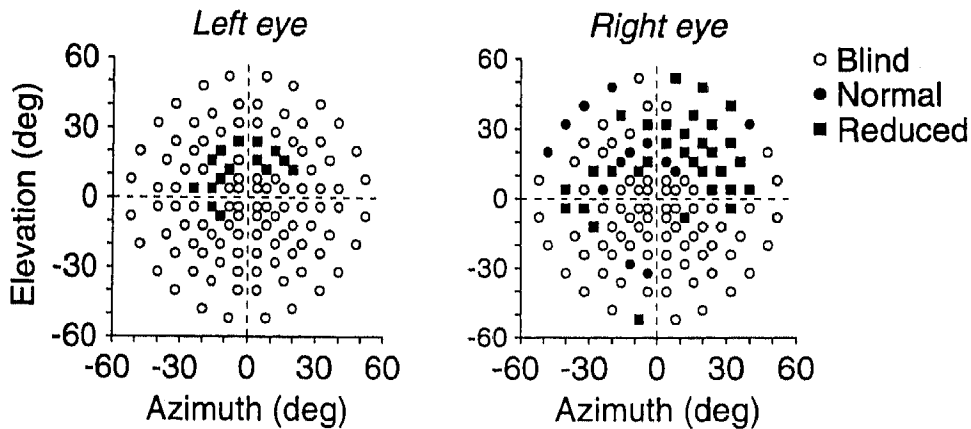
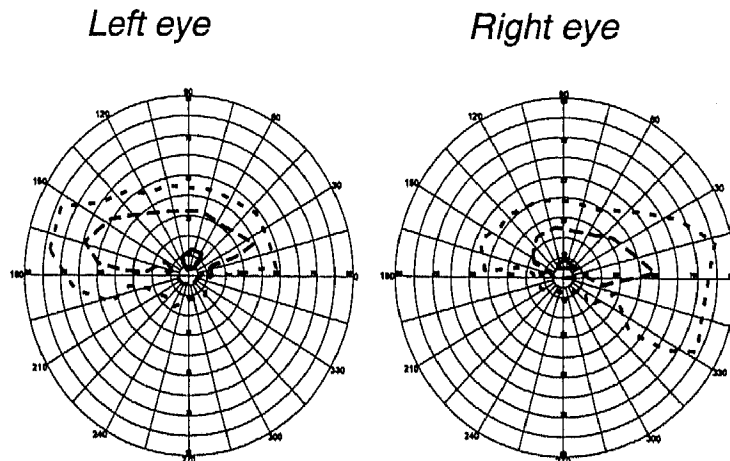
MS**FJ**

Fig. 2: Visual field perimetry in MS (top: Octopus; at 7:6 y) and in FJ (bottom; Goldman; at 19.3 y). For FJ the concentric polygons correspond (from inner to outer) to progressively increasing stimulus size and intensity, i.e., I_2 , I_4 , and V_4

Structural MRI (Fig. 1) showed important enlargement of the occipital horns of the lateral ventricles, bilateral atrophy or destruction of the cortex of the occipital pole and of the medial surface of the hemisphere. This included the cortex of the calcarine sulcus, of the lingual and fusiform gyri, namely, most of areas 17 and 18 of Brodmann corresponding to areas V1, V2, and V3 (Zilles & Clarke, 1997) and extended as far as the

parieto-occipital sulcus. V4, located in the collateral sulcus (Hasnain et al., 2001), might be involved as well bilaterally. More dorsally, scarring of the white matter predominated. The lesion resembled that of MS but was less extensive dorsally and slightly more extensive ventrally, particularly in the right hemisphere, which, unlike in MS, was more affected than in the left. There was also a hyperdense signal in the left prefrontal cortex and in both

cerebellar hemispheres, with prevalence on the left. Ophthalmologic examination at the age of 19:3 showed a visual field bilaterally restricted to a 30 to 40 degree crescent in the pericentral superior hemifield, rather similar to that of MS (Fig. 2). Visual acuity was estimated 3/60 in the right eye and 1/60 in the left eye.

Control subjects

To evaluate results when normative data were not available, as it was the case for MS in some of the tests, we performed the same studies with age-matched children, who had normal or corrected to normal vision and no history of neurological disorders. The results in MS, were compared with those from two girls, JU and CH, aged 4 and 4.5 years, respectively, and from two boys, LH and JH, both 5 years of age. FJ's data are compared with those of a normal adult male, 38 years of age. The consent of all subjects and of their parents was obtained before each experiment, according to the declaration of Helsinki (BJM 1991; 302:1194) and to the Ethical committee of the Institution.

METHODS AND RESULTS

General cognitive evaluation and assessment of visual functions

Standard tests. We tested MS at ages 7:8 to 7:11 and at 10:6 with procedures comparable to those used with FJ (Table 1). At the verbal scale of the WISC-III (Wechsler, 1996), she achieved a verbal IQ of 95. Given her difficulties in visual perception, only the «block design» sub-test was administered out of the performance scale, at which she obtained a low score, although within the normal range. She was modestly impaired in color perception (Ishihara) and more severely, in

stereoscopic vision.

She successfully performed the Test of Visual-Perceptual Skills (Gardner, 1982), although extremely slowly, keeping her eyes at a few centimeters from the visual stimuli and comparing the different drawings, detail by detail. Interestingly, her performance was low in the three visual sub-tests that involved form recognition (shape constancy, figure-ground segregation, and closure).

At sub-tests of the K-ABC (Kaufman & Kaufman, 1993), she was especially poor at the «magic window», in which colored drawings of objects are progressively presented through a narrow window, and at the «form recognition», in which partial drawings of objects must be identified. She also had severe difficulties in a Poppel-reuter-like test of overlapping figures, usually managing to identify only one out of the four or five super-imposed line drawings.

At the Birmingham Object Recognition Battery (Riddoch & Humphreys, 1993), MS obtained mixed results. She performed normally in the position of gap match task and in the foreshortened view task that requires matching the same objects viewed from different viewpoints. The scores in other visual sub-tests (length match, size match, and so on) were just below cut-off. Her performance was clearly impaired in form-recognition sub-tests (e.g., object decision), especially, when the forms were partly entangled (embedded letter and object identification). Such difficulties were also observed in the recognition of objects presented in separate parts, as in Hooper's visual organization test.

Given MS's visual difficulties, spontaneous drawing was rather good, as was copying geometrical figures in Bender's Copy Test (Santucci & Pêcheux, 1967). Finally, visual memory, both short-term and long-term, as assessed with the Complex figure of the Batterie d'Efficiency Mnésique (BEM; Signoret, 1991), the Visual Retention Test (Benton, 1965), and the visual memory sub-tests of the TVPS, was good.

The recognition of familiar (family pictures) and unfamiliar faces (face recognition test) was normal. By contrast, MS experienced severe difficulties in visual search tasks (Bells' test; Gauthier et al., 1989). Finally, MS's literacy skills were preserved: Her reading was relatively accurate although slow (BELEC, Mousty et al., 1994; L3, Lobrot, 1967). She had difficulties with words or texts written with a usual font size, but her reading of texts written with larger letters was fluent. Her spelling was normal (O2, Lobrot, 1967). A questionnaire of spatial orientation (Groenveld et al., 1994) did not reveal particular problems.

FJ was tested at the age of 18:6 and 20:6 (Table 1). At the WAIS-R (Wechsler, 1989), he obtained a verbal IQ of 52. As opposed to MS, FJ has a moderate mental retardation that is probably related to the additional lesions seen outside the visual cortex, in particular in the prefrontal cortex. This, however, does not at all explain the very poor results on visuoperceptual tasks, in which very young or mentally retarded children can succeed. The performance scale could not be administered because the patient did not fulfill the basic visual requirements for most of the tasks. The 'block design' sub-test was administered, however, and FJ obtained a very low score. Furthermore, FJ presented a slight articulation difficulty affecting fricative consonants. His language production and comprehension in usual communication settings was normal: FJ always answered adequately to questions, and the utterances produced did not contain lexical or grammatical errors. Nevertheless, most utterances had a simple structure (embedded phrases were not observed in a 20-min conversation recording), and FJ had difficulties in structuring his discourse as is usually observed in individuals with a low IQ. He also showed certain difficulties in the last items of Ishihara's color perception test and did not show any sign of stereoscopic vision at the Stereo Test.

FJ was severely impaired at all sub-tests of the Test of Visual Perceptual Skills. No difference was observed between the right and the left eye at monocular testing.

At the K-ABC, FJ was totally unable to identify any object in the magic-window sub-test. He correctly identified only a few persons in the person recognition sub-test and only one figure in the figure recognition sub-test.

With Poppelreuter-type overlapping figures, FJ managed to identify only one object of the four or five contained in the figures.

At the Birmingham Object Recognition battery, all results were below norms. The difficulties were especially important with overlapping figures and letters. Isolated or juxtaposed letters were easily identified, although FJ had not yet managed to acquire basic literacy skills. There were massive difficulties in identifying animals or objects presented in separated parts (Hooper, 1983). In drawing, he could copy simple geometric shapes (circle, square, triangle, but not diamond). Objects drawn upon command (man, house, flower, etc.) were usually identifiable, but very sketchy. All tests involving the copy of more complex figures led to very poor results. There was a slight deviation towards the left in the bisection of horizontal lines. In a task where he had to cross out short lines that are pseudo-randomly placed on an A4 sheet, he omitted 3 of 32; all the omissions were located on the right-hand side. In a more complex test of visual neglect (Bells' test), FJ experienced severe difficulties in finding the target drawings and made a high number of confusions with distractors. Additionally, 5 of the 6 bells that were crossed were either on the midline or on the left-hand side.

Finally, FJ answered correctly most questions about shape, size, and color of objects, indicating the presence of (at least partial) mental images of objects. He was also able to describe verbally, or

Table 1. Results of the neuropsychological examinations performed with MS at ages 7:8 to 7:11 and 10:6 (#) and with FJ at ages 18:9 and 20:6 (#)

TESTS and SUB-TESTS	INDEXES	RESULTS		NORMS (means +/- 1 s.d.) or COMMENTARIES
		MS	FJ	
WISC-III/WAIS-R				
Information	Verbal IQ	95	52	100 +/- 15
Similarity	Standard Score	9	3	10 +/- 3
Arithmetics	Standard Score	10	4	10 +/- 3
Vocabulary	Standard Score	9	2	10 +/- 3
Comprehension	Standard Score	7	4	10 +/- 3
Digit Span	Standard Score	11	1	10 +/- 3
Block Design	Standard Score	10	3	10 +/- 3
	Standard Score	7	1	10 +/- 3
Color perception				
Ishihara	Raw Score	6/8 [#]	5/8	Errors on the 2-3 most difficult items
Stereoscopic vision				
Stereo tests	Raw Score	2/9 [#]	2/9	Performance at chance level
Test of Visual Perceptual Skills				
Visual Discrimination	Perceptual Quotient	92	48 [#] for age 12*	100 +/- 15
Visual Memory	Median Perceptual Age	7:8	4:10 [#]	10 +/- 3
Visual-Spatial Relationships	Standard Score (Raw Score)	12 (12/16)	2 [#] (3/16) for age 12*	10 +/- 3
Visual Form Constancy	Standard Score (Raw Score)	11 (9/16)	6 [#] (8/16) for age 12*	10 +/- 3
Visual Sequential Memory	Standard Score (Raw Score)	11 (12/16)	3 [#] (9/16) for age 12*	10 +/- 3
Visual Figure-Ground	Standard Score (Raw Score)	5 (3/16)	1 [#] (0/16) for age 12*	10 +/- 3
Visual Closure	Standard Score (Raw Score)	10 (10/16)	4 [#] (8/16) for age 12*	10 +/- 3
	Standard Score (Raw Score)	7 (5/16)	2 [#] (3/16) for age 12*	10 +/- 3
	Standard Score (Raw Score)	6 (3/16)	2 [#] (2/16) for age 12*	10 +/- 3
K-ABC				
Magic Window	Standard Score (Raw Score)	1 (1/15) for age 4:10*	1 (0/15) for age 4:10*	10 +/- 3
Person Recognition	Standard Score (Raw Score)	9 (9/15) for age 4:10*	2 (3/15) for age 4:10*	10 +/- 3
Form Recognition	Standard Score (Raw Score)	1 (5/25) for age 7:10	1 (3/25) for age 12,10*	10 +/- 3
Poppelreuter-like Overlapping Figure Test				
	Raw Score	5/19	4/19	Recognition of 1 element out of the 4-5 contained in each figure

Birmingham Object Recognition Battery							
Length Match	Raw Score	23/30	21/30				26.9 +/- 1.6, cut-off score = 24**
Size Match	Raw Score	21/30	23/30				27.3 +/- 2.4, cut-off score = 23**
Orientation Match	Raw Score	17/30	15/30				24.8 +/- 2.6, cut-off score = 20**
Position in Gap Match	Raw Score	32/40	25/40				35.1 +/- 4.0, cut-off score = 27**
Item Match	Raw Score	—	21/32 [#]				30.0 +/- 2.2, cut-off score = 26**
Object Decision (easy)	Raw Score	22/32	16/32 [#]				30.5 +/- 1.4, cut-off score = 28**
Foreshortened View Task	Raw Score	17/25	11/25 [#]				21.6 +/- 2.6, cut-off score = 16**
Minimal Feature Task	Raw Score	22/25 [#]	17/25				23.3 +/- 2.0, cut-off score = 19**
Single Letter Identification	Raw Score	18/18	16/18				
Double Letter Identification	Raw Score	18/18	16/18				
Embedded Letter Identification	Raw Score	8/18	12/18				
Single Object Identification	Raw Score	16/20	10/20				
Double Object Identification	Raw Score	17/20	8/20				
Embedded Object Identification	Raw Score	12/20	6/20				
Hooper's visual organization test	Raw Score	6.5/30 [#]	1.5/30 [#]				Performance much lower than that of normal 5-year-old children (17-18 +/- 3)***
Bender's Copy Test	Raw Score	29/81	24/81				MS: centile 25-50 FI: <<< centile 25 for age 14*
Visual Memory Complex Figure (BEM)							Norms for Adults (FJ)
Immediate copy	Raw Score	9.5/12 [#]	5/12				9.5-11.0 years (MS)
Differed copy	Raw Score	7.5/12 [#]	4/12				9.6 +/- 1.4
Benton's Visual Retention Test	Raw Score	6/10	—				9.0 +/- 2.2
Benton's Face Recognition Test	Corrected Score	43	36				very superior
Visual Search (Bells' test)	Raw Score	20/35	6/35				Normal** = 41-54, <37 = very impaired
Literacy							33.3 +/- 1.2**
Degraded letter identification	Raw Score	—	44/51 [#]				Slight difficulties
Regular word identification (BELEC)	Raw Score	24/24 [#]	—				3 rd grade level
Irregular word identification (BELEC)	Raw Score	18/24 [#]	—				3 rd grade level
Written comprehension (L3)	Raw Score	14/36 [#]	—				1 st grade level (slow)
Spelling (O2)	Raw Score	23/30 [#]	—				4 th grade level

*upper limit of the available norms

**norms for adults

*** from Spreen & Strauss (1998)

recognize by touch or by hearing, objects that he could not recognize visually.

In conclusion, MS and FJ are impaired in similar visual tasks, FJ more severely so.

Cognitive contours

The assessment of this domain was carried out when MS was 10:6 and FJ 20:6. All cognitive contour tests involved the visual presentation of Kanisza-type figures (without time limit). Different response modes were used, as follows:

- the verbal description of six figures,
- the copy of three figures (administered to MS only, given FJ's difficulties in drawing), and
- a two-choice procedure to point to six figures (Kartsounis & Warrington, 1991).

In summary, MS easily identified all subjective contours presented in all three tasks. FJ correctly detected 4/6 contour shapes in the first task, and responded correctly to 5/6 items in the last. The slightly above chance results suggested that FJ has little sensitivity to cognitive contours.

Psychophysical experiments

General psychophysical methods. For all psychophysical experiments, the stimuli were presented on an Eizo T-560i monitor, driven by an AT Truevision Vista graphics board mounted in a PC. The screen refresh rate was 104 Hz, interlaced. Testing was performed in a dimly illuminated room. All experiments were designed as 2-, or 3-alternative forced choice procedures. In all experiments, we used the method of constant stimuli. We first performed a variable number of initial trials to determine five values of the experimental variable that would span the subject's performance range from chance to 100% correct responses. These 5 stimuli were then presented for

a minimum of 20 blocks, within which the stimuli were presented in pseudorandom order. Psychometric functions were fitted to the data by probit analysis (Finney, 1971), and thresholds were defined as the 75% (for 2AFC), or 66% (3AFC) correct points. The stimuli and analyses specific to each experiment are described with the results.

The subjects gave their responses verbally, or in some cases, with predefined hand movements, and the responses were recorded in the PC by the experimenter. The subjects were verbally informed about their responses after each trial (right or wrong). The subjects' attention and motivation levels were kept as constant as possible by verbal encouragement. A session was stopped when their attention appeared inadequate.

Experiment 1: Contrast sensitivity and motion detection. The stimuli were square patches of sinusoidal gratings. For measuring the spatial contrast sensitivity functions (CSF), a single static grating was presented either on the right or on the left side of monitor, the position being pseudorandomly changed between the presentations. The space-averaged luminance of the patch was equal to that of the background (32 cd/m²). At the viewing distances we used (70 to 90 cm), the screen subtended 24 to 19 degrees and the patches 4.1 to 3.2 degrees. For the lower spatial frequencies, the patch size was increased to ensure that at least three cycles of the grating were visible.

Each stimulus remained visible until a response was given, and the task was to indicate the location of the target. We measured the contrast detection threshold for five to six different spatial frequencies. The inverse of the contrast detection threshold (contrast sensitivity) was then plotted as a function of spatial frequency. These points were fitted with a double-exponential function of the form:

$$k_s (\omega k_\omega)^\alpha e^{-\beta \omega k_\omega}$$

where ω is spatial frequency. The four free parameters affect primarily the steepness of the low (α) and high frequency (β) portions of the curves, and shifts along the horizontal (k_ω), and

vertical (k_s) axes. This function accounts well for contrast sensitivity data (Williams et al., 1981). To measure the ability to detect motion and to identify its direction, we presented the patch in the center of the screen, and the gratings were drifting either to the left or to the right. The direction of movement was pseudo-randomly changed between presentations. The task was then to indicate if a grating had been detected and the drift's direction. We measured the subject's ability to detect and identify the direction of gratings drifting at various temporal frequencies (0.5 to 32 Hz, in octave steps).

MS was tested at ages 4, 4:6, 5, and 8 (Fig. 3). Despite the extent of her lesions, MS already performed well in this task at the age of 4, being only slightly less sensitive than normal children tested in exactly the same conditions (Fig. 3A). Her visual acuities, obtained from extrapolation of the curves to a sensitivity of 1, were 17.5 c/deg for binocular vision (compared to 23 c/deg for the 3 control children we tested), 16.7 c/deg in the left eye, and 12.5 c/deg for the right eye.

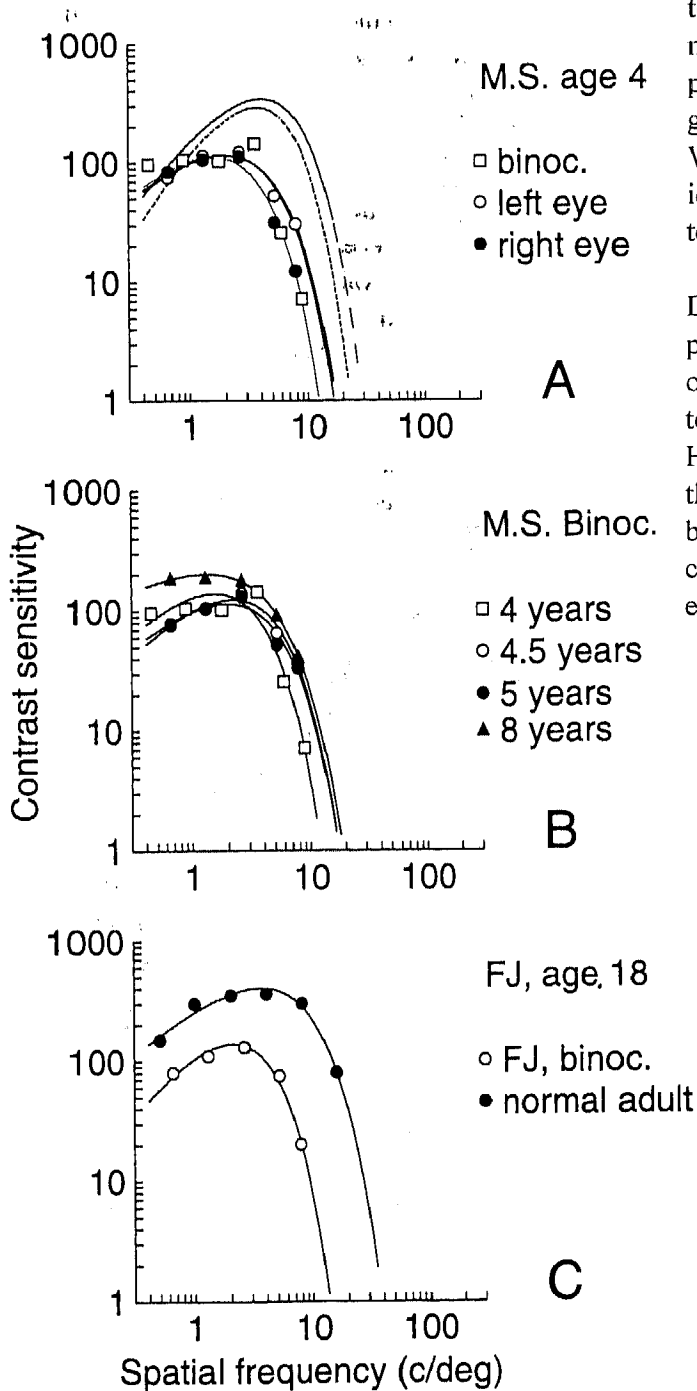


Fig. 3: Contrast Sensitivity Functions (CSF) for MS, FJ, and control subjects. The inverse of the contrast detection thresholds, namely, contrast sensitivity, are plotted for five or six spatial frequencies. Each data set was fitted with a double exponential function (see text), shown by the full lines through the data points. (a) Monocular and binocular CSFs when MS was 4 years old. □, binocular viewing; ○, left eye; ●, right eye. The dashed curves replotted from a published study (Bradley & Freeman, 1982) showing the averaged binocular CSF for a group of 6 children aged 4.5 to 6.5 y. The other curve shows the averaged binocular CSF for three normal control children, aged 4 to 5 y. (B) Binocular CSF for MS at three different ages. □, age 4; ○, age 4:6; ▲, age 8. (C) Binocular CSF for FJ at age 18 (○) and for a normal subject (●).

Figure 3B shows that over 4 years, her performance in this task did not significantly improve, except for a slightly better sensitivity for low spatial frequencies at 8 years of age. Such an improvement is, however, expected from normal maturation alone (see Bradley & Freeman, 1982).

The motion detection and identification tests were performed at age 4:6. MS's sensitivity to moving gratings of different spatial (1.3, 5.2, and 7.8 c/deg) and temporal frequencies was nearly normal (data not shown). For the spatial frequencies of 1.3 and 5.2 c/deg, we measured the threshold at four different temporal frequencies: 4, 8, 16, and 32 Hz. For the 7.8 c/deg grating, we used only 4, 8, and 16 Hz because the fastest drifting grating (32 Hz) was, even at 100% contrast, invisible to MS. In addition, MS's thresholds for identifying the motion of the drifting gratings were invariably the same as those for detecting the gratings. In other words, as soon as a drifting grating was visible, she could reliably identify its drift direction.

The results of this experiment suggest that despite her extensive lesions, most information about the physical properties of a visual stimulus arrive at, and can be processed by, MS's visual cortex. Therefore, the visual deficits of MS (see below) cannot be attributed solely to deficits at the early levels of the visual pathways.

FJ was tested at the age of 18 y, in binocular vision (Fig. 3). For all the spatial frequencies tested, FJ's sensitivity was significantly lower than that of a normal adult (age 38) tested in exactly the same conditions. The contrast sensitivity curve was displaced toward lower than normal frequencies and practically superimposable to that of MS (Fig. 3). The extrapolation of the curve to a sensitivity of 1 yields a grating acuity of 13.9 c/deg, which is much lower than that of the normal adult (38.5 c/deg), and slightly lower than that of MS.

Concerning motion, FJ was asked to catch balls and pick up rolling beads during clinical examination and appeared to have no difficulties

in this domain.

Experiment 2: Vernier acuity. The stimulus consisted of two vertical line segments. The upper, longer segment remained in a fixed position from trial to trial, whereas the lower segment could be presented either to the right or the left of the upper segment (see the inset of Fig. 4 for a schematic representation).

The task was to indicate whether the lower segment is displaced to the left, to the right, or is aligned relative to the upper one. We measured the minimal offset necessary for reliable, correct responses. Viewing was binocular. In MS, the upper segment subtended 5.6 deg in length and 5.1 min in width. The lower segment had the same width, but subtended 2.84 deg in length. Both segments had a luminance of 64 cd/m² and were presented on a low luminance background (2 cd/m²). The vertical distance between the two segments was 1.2 min.

In FJ, the stimuli, procedure, and analysis were the same as those described above, except that the viewing distance was double that used with MS. Thus, the upper segment subtended 2.8 deg in length and 2.6 min in width, whereas the lower segment had a length of 1.4 deg. The gap between the segments subtended 0.6 min.

MS was tested at ages 4:6, 5 and 8 (Fig. 4) At age 4:6, she showed significant deficits compared with the controls, her Vernier threshold (10.8 min) being 6.8 times higher than the averaged threshold of the normal subjects (1.6 min). She thus showed a higher degree of impairment in Vernier acuity than in grating acuity, in which she differed from normal by a factor of 1.3 only. Six months later, her Vernier acuity deficits had substantially decreased. At the age of 5:6, MS's performance had improved, further reaching a threshold of 5 min, but it then remained stable until age 8. Although her relative deficits in this task diminished over the years, they remained significant.

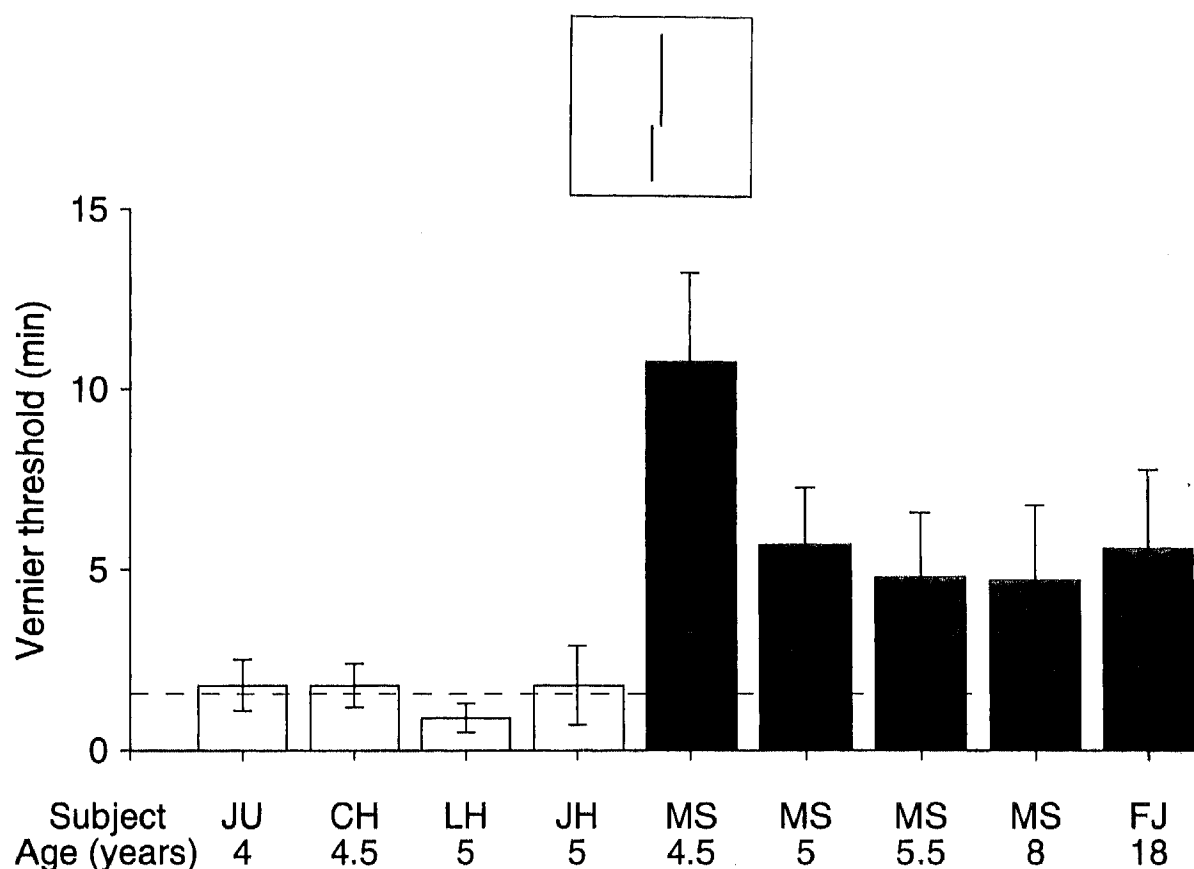


Fig. 4: (A) Vernier offset thresholds for MS at four different ages compared with those of FJ (age 18) and normal children. The error bars show the SE for the threshold estimates. The inset above the graph shows the stimulus configuration for that experiment. The subject's task was to decide whether the lower line segment was aligned with the upper segment and to indicate whether it was displaced to the left or to the right.

FJ's threshold at the age of 18:8, was 5.6 min, which is comparable to that of MS at age 5 y. A normal adult (age 38), however, tested in exactly the same conditions, had a threshold of 0.6 min, a value agreeing with numerous hyperacuity tasks. Moreover, FJ's performance was also much worse than that of the three normal subjects aged 4 to 5 y (see Fig. 4). Thus, FJ's performance in this task was considerably impaired. In a second examination at age 20:6, FJ had a threshold of 5.2 (± 0.8) min.

Experiment 3: Figure-ground segregation. We designed two different tasks requiring line segments to be segregated from background and bound into

a figure. In the first, the subject had to determine the orientation of a rectangle whose texture differed from that of the background (the 'rectangle orientation' task). In the second, the subject had to identify a shape formed by collinear line segments embedded in randomly oriented 'distractors' (the 'shape identification' task). When compared with experiments 1 and 2, these tasks represent a new level of complexity as they require the subject not only to detect the different elements of the stimulus and to judge their relative positions and orientations but also to bind them into coherent ensembles.

Rectangle orientation

Figures 5A and 5B are examples of the stimuli used in this experiment. The display subtended 22.3 deg, and contained 16 by 16 equally spaced elements. The target rectangle was 4 deg in width and 10 deg in height. The line segments subtended 0.9 deg, and luminance was 62 cd/m². Background luminance was 2 cd/m². For the stimulus shown in Fig. 5A, the orientation of the lines was pseudo-randomly varied from trial to trial, but the angle between the rectangle's elements and those in the background were kept at 90 deg. The subject had to say whether the rectangle was presented vertically ('standing'), or horizontally ('lying'). We measured the minimal presentation duration necessary for the reliable detection of the rectangle's orientation, which, like the rectangle's position, was pseudo-randomly varied from trial to trial. The same task was also performed with figures (the rectangles) defined by other visual attributes.

- First variation: small rectangles or triangles replaced the line segments, the first used for the background and the second for the figure (Fig. 5B).
- Second variation: the rectangle was defined by segments with a small, subthreshold angle difference from those in the background (10 deg for a 100 ms presentation), and moved (horizontally or vertically) across the screen, while the background remained static.
- Third variation: the line segments in the rectangle were oriented as those in the background, but differed in luminance.
- Fourth variation: the elements defining the figure were small squares (0.3 deg side), in which the colors differed from those in the background. The squares making the figure and those in the background were of equal luminance. Viewing was always binocular.

MS was tested at the ages of 4:6, 5, 5:6 and 8 (Fig. 5C). MS's thresholds for the stimulus shown in 5A

showed a dramatic 70-fold improvement over a period of 1.5 years, followed by a slower recovery.

At the age of 4.5 y, MS could locate the line segments that were oriented differently from background and could identify the orientation of isolated line segments (she could easily detect the smallest deviation from vertical that we could produce on our monitor for a 0.9-deg-long segment). Yet, she was unable to detect the rectangle defined by the iso-oriented line segments, unless she could observe the stimulus for more than 15 sec. Similarly, she was unable to detect the rectangle defined by elements with different shapes than those in the background (the first variation), even though she could easily identify these shapes presented in isolation. By comparison, normal children (aged 4 to 5 y) achieve correct identification of the target's orientation with presentation times as low as 0.08 sec. For them, the rectangle 'pops out' effortlessly, whereas MS had to serially study individual elements to solve the task.

We reasoned that her difficulties in the figure-ground segregation task could be attributed to 'crowding' effects. We thus repeated the task with increasing display sizes, in which the inter-element spacing was doubled, but all other parameters were kept constant. Despite the increased inter-element spacing, MS's performance remained the same (the threshold presentation duration remained superior to 10 sec).

At the age of 5 y, MS had become capable of identifying the rectangle's orientation with presentation times of 0.53 sec. Her behavior at this age was clearly different from the serial searching she had displayed 6 mo earlier. At age 5.5 y, her performance had further improved, and her threshold was 0.22 sec, which is closer to normal performance. At age 8 y, her performance had still improved, but was still slightly poorer than that of the control children. Similar results (data not shown) were obtained with the rectangle defined by the different shapes. With those, all the measured

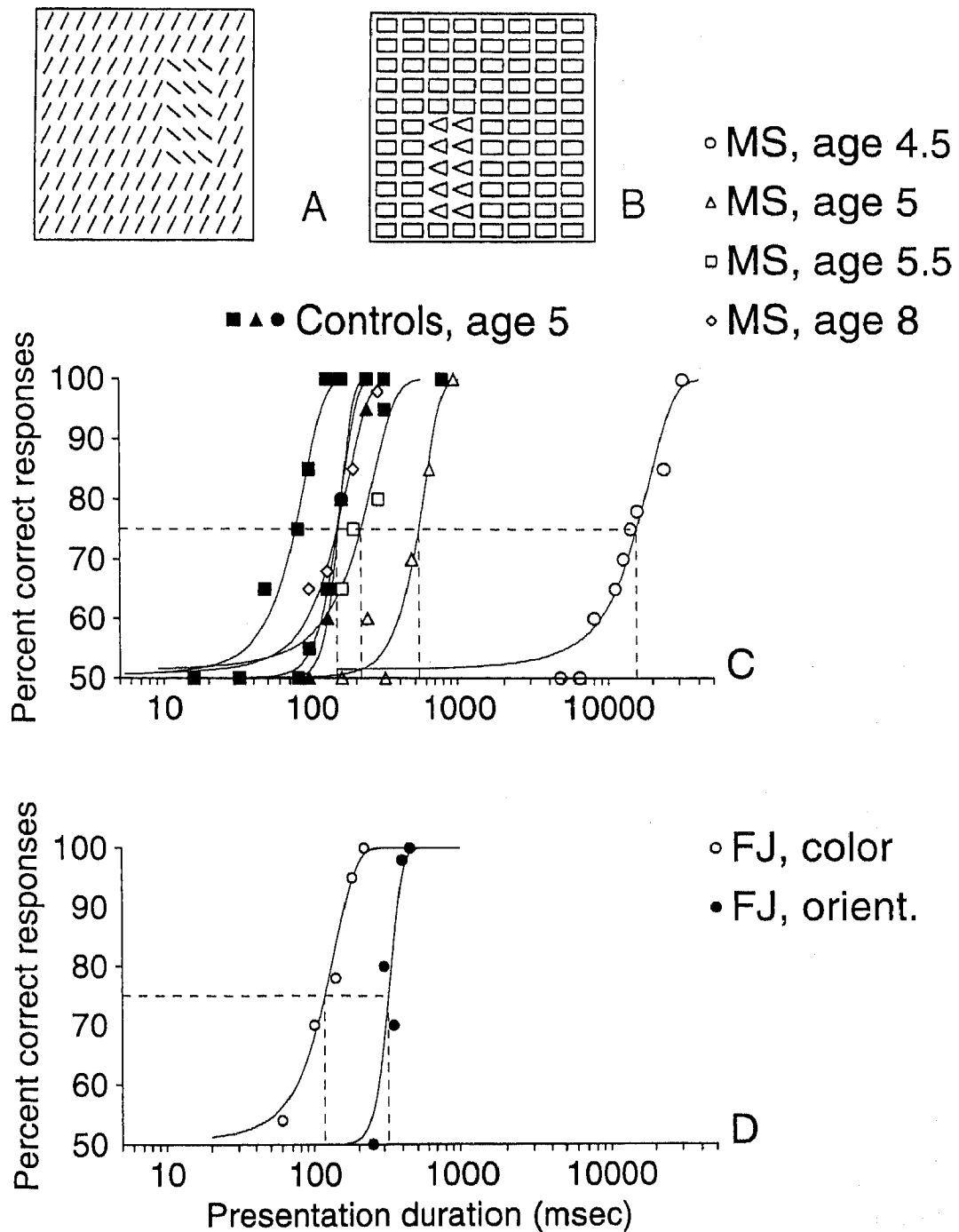


Fig. 5: Performance of MS, FJ in the rectangle orientation task. (A), (B): The stimuli. See text for explanation. (C) Performance of 3 control subjects (all aged 5) and of MS at ages 4:5, 5, 5:5, and 8, using the stimulus shown in (A). Horizontal dashed line, 75% correct threshold level; Vertical dashed lines, MS thresholds. See text for explanation. (D) Performance of FJ at age 19 on the same task using stimulus (A) (●) and showing a rectangle defined by elements (small squares) varying in color (○). Notice that the performance with (A) is close to that of MS at age 5, whereas the performance using colors is faster.

thresholds were higher than those obtained with the line segments by a factor of approximately two, but the relative performance of MS compared with that of control children was the same.

In the other variations of this experiment, MS showed no difficulty. She could identify the rectangle's orientation as quickly and reliably as did the control children, when the rectangle was defined by luminance, motion, or color differences relative to background. Only when the rectangle was defined solely by texture features, such as the segments' orientation, or by different shapes did she have difficulties in performing.

FJ was tested at the age of 18:8 for the 'orientation' and 'color' variants of the experiment (Fig. 5D). In the 'segment orientation' condition, FJ could identify the orientation of the rectangle in 0.322 sec. This performance is worse than that of MS at ages 5:5 and 8, and much worse than that of a normal adult tested in the same conditions (0.025 to 0.030 sec). When the rectangle was defined by color differences, he could respond in 0.117 sec, which is better than the 'segment orientation' condition, but still considerably worse than the normal adult performance (0.025 to 0.030 msec, equal to the performance with oriented segments).

Shape identification

In the second figure-ground segregation task, we used stimuli like those schematically illustrated in Fig. 6. The grid contained a variable number (with a maximum of 32 by 32) of non-intersecting line segments. The other stimulus characteristics were the same as those of the 'rectangle orientation' experiment. The location and orientation of each of the background elements (distractors) were random. The subjects had to detect whether a figure defined by the collinear segments was a triangle (with a base made of 2 segments and sides of 3 segments each), square (2 by 2 segments), or rectangle (3 by 1 segments). The shape of the

figure and its location were pseudorandomly varied from trial to trial. As in the 'rectangle orientation task', we measured the minimal presentation duration for the reliable identification of the figure as a function of the number of distractors and for two different segment lengths (0.1 and 0.4 deg). Viewing was binocular.

MS was tested at age 7.5 y, using different segment lengths and in comparison with a control child of the same age (Fig. 6). For each segment length, MS's performance was normal in the presence of a small number of distractors, but started to fall off rapidly when the number of distractors was increased. For example, for a segment length of 0.1 deg, her threshold presentation duration was below 100 ms for 50 or less distractors and rose to almost 400 ms for 75 distractors. With 100 distractors, she was unable to perform the task. For comparison, the control subject's performance was unaffected by 75 distractors, and started to deteriorate only in the presence of 125 or more distractors. Increasing the segments' length made the task easier both for MS and for the normal child, but did not change the pattern of our results.

FJ was tested at the age 20:6 (Fig. 6). Above 75 distractors, his performance began to deteriorate, and the difficulty rose with the increasing number of distractors, but less than that in MS.

DISCUSSION

The patients

Many striking similarities can be seen between MS and FJ. In both patients, the lesions were due to focal ischemic damage secondary to bacterial meningitis early in life. The location of the occipital lesion is similar, involving most of the visual cortex along the calcarine sulcus, inclusive of Brodmann's areas 17 and 18, and corresponding to areas V1,

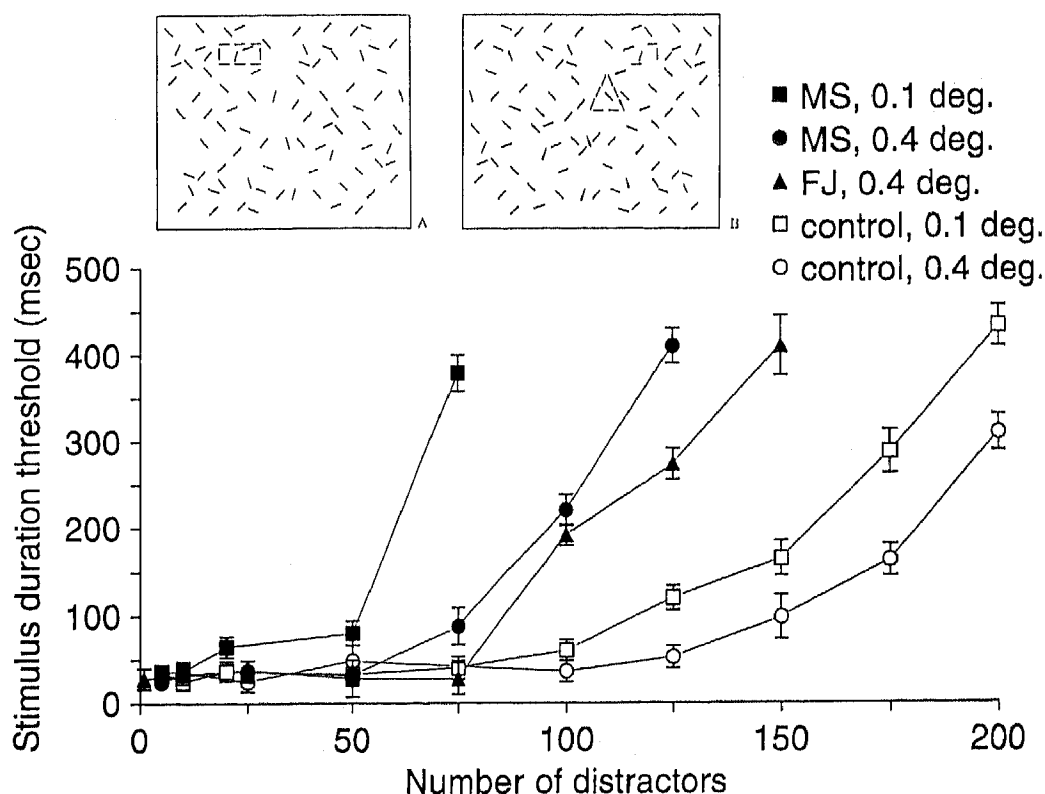


Fig. 6: Results of the 'shape identification tasks in MS and FJ. The subject had to identify the shape (rectangle in A, triangle in B) presented among the distractors. We measured the minimal presentation duration for reliable identification, for two different segment lengths, and different numbers of distractors. We plotted the presentation duration as a function of the number of distractors. ■ (normal subject, age 8), □ (MS, age 7.6), - segment length of 0.1 deg; ● (normal), ○ (MS) - 0.4 deg; ▲, FJ, age 20.6, 0.4 deg segments. Error bars show the SE of the threshold estimates.

V2, and V3 (Zilles & Clarke, 1997). The lesion of the visual areas is associated with a comparable visual field defect. The preserved portion of the visual field is a crescent situated in the upper hemifield, possibly slightly wider for FJ than for MS¹. In both, a comparably small portion of the

visual cortex near the occipital pole is activated in fMRI images. The visual functions of MS at the age of 8 and of FJ at 18 are similar. Visual acuity, contrast sensitivity and Vernier visual acuity are impaired to a comparable degree. Despite some difficulties on the Ishihara test, at least a certain amount of color perception was present in both

¹ The lesion resembles that caused by a shell wound in a Japanese soldier described by Inouye (quoted by Grüsser & Landis, 1991, see their Fig. 9.12). The spared field is not perfectly corresponding for the two eyes. The non-correspondence of visual field scotomatas caused by occipital lesions has been described in the case of adult lesions (reviewed in Grüsser & Landis, 1991) and it violates textbook notions of the

organization of the visual pathways. No clear explanation exists for this finding, and in any case, the explanation is likely to be more complicated in our patients as the lesions occurred at an age when the two eyes are still competing for cortical space.

MS and FJ, and indeed, they could solve the rectangle orientation task relatively easily when the figure was defined solely by color differences with the background. Both patients lost stereoscopic vision, a not surprising finding given their strabismus. The perception of simple shapes was preserved. Both were impaired in detecting complex images, particularly those defined by linear textural elements, and in identifying overlapping figures of the Poppelreuter type or of incomplete figures.

There are also important differences between MS and FJ. The most striking difference is that globally, FJ was more severely impaired in visual tasks than MS. The lesion occurred at a younger age in MS (33 wk, post-conception) than in FJ (7 mo post-natal). The lesion was more severe in the right hemisphere in FJ and in the left in MS. In FJ, the lesion involved non-visual areas that are probably responsible for his cognitive difficulties.

The similarities between these two patients justified their comparative study. The differences, on the other hand, might be useful for understanding the pathogenesis of the deficit and the possible mechanisms of functional recovery (Knyazeva et al., 2002).

The nature of the deficit

The deficits observed in our patients fall within the category of visual agnosia and are close to those associated with 'apperceptive visual agnosia' (Humphreys & Riddoch, 1987; Farah, 1990; Grüsser & Landis 1991; Grossman et al., 1997, for review).

Apperceptive agnosia covers cases of impaired recognition due to the failure to achieve a fully specified percept from visual information, in spite of adequate, or at least not severely impaired elementary sensory abilities...De Renzi and Lucchinelli (1993).

In apperceptive agnosia

...tasks that manipulate perceptual difficulty and/or complexity and in particular those in which the identifying features are obscured or distorted, appear to be particularly vulnerable Warrington and James (1988).

Such patients, however, perform well on simple shape-detection and discrimination tasks, in color perception, and have intact visual semantic knowledge (Warrington & James, 1988).

The conditions described above apply to our patients. In particular, there was a clear dissociation between the contrast sensitivity functions and the performance of the patients when objects had to be reconstructed from local features. Both patients could recognize simple shapes, as in the shape identification task, but the recognition was progressively impaired when distractors were added to the shapes. The patients could also identify single or double letters, but were impaired in embedded letter identification (Table 1). So, like other patients with apperceptive visual agnosia (Humphreys & Riddoch, 1987; Warrington & James, 1988; Farah, 1990; Grüsser & Landis 1991; Kartsunis & Warrington, 1991; De Renzi & Lucchinelli, 1993; Mizuno et al., 1996; Grossman et al., 1997, for references), they had the greatest difficulties in recognizing objects from superposed or incomplete line contours, but not when fully drawn and in isolation.

The heuristic value of classifying our patients as 'apperceptive agnostics' is nevertheless limited.

- First, apperceptive agnosia can be associated with different degrees of perceptual impairment. Despite comparable results in certain tests of basic visual functions, MS and FJ differed in tests of visual perceptual skills, in the K-ABC test, in Benton's face recognition test, and in the psychophysical figure-ground discrimination tests, for which FJ was usually

more severely impaired. Also, in our patients, the deficits are limited to situations in which to perceive the figure, they are forced to identify the relative position of lines and texture elements, and to connect them into a coherent whole. Such deficits are absent when the patients can use luminance, color, or movement for figure identification. MS and FJ may, therefore, represent a special case of visual agnosia, possibly attenuated by compensatory reorganizations of the juvenile brain.

- Second, as noticed by others, apperceptive agnosia has “fuzzy boundaries” (De Renzi & Lucchinelli, 1993). The boundaries between apperceptive agnosia and other agnosias—particularly ‘visual form agnosia’ (or pseudo-agnosia) or ‘integrative agnosia’—are not easily traced, particularly when one addresses the nature of the underlying deficits (for discussion see Milner et al., 1991; Butter & Trobe, 1994).
- Third, the nature of the deficit underlying apperceptive agnosia is unclear. The two most frequently evoked mechanisms are either that the world is viewed through a “peppery mask” or that a perceptual grouping process is impaired (discussed in Vecera & Gilds, 1998). The second interpretation refers to the notion that the initial stages of visual perception involve the segmentation of the object into multiple features that are recognized by different neurons, which are subsequently bound into a coherent neuronal assembly (see below). Although we share the view that an impairment in the process above might be the ‘core deficit’ in agnosia of the apperceptive, or integrative type, complications arise because certain binding processes may be preserved and others lost in the same patient, and that this can differ across patients. Our patients had difficulties in perceiving incomplete line drawings of objects but did not fail on the cognitive contour illusions task, which clearly

requires perceptual binding. In contrast, the patient described by Kartsounis and Warrington (1991) failed on the cognitive contours as well. Because perception fails with increasing figure complexity, in explaining apperceptive agnosia “a limitation in the cognitive resources that are available for processing demanding material within the visual modality” has also been invoked, in addition to the “compromised integrity of the visual perceptual apparatus” (Grossman et al., 1997).

- Finally and most important, apperceptive agnosia was defined in adults—namely, in those whose ability to visually recognize shapes, objects, and so on is known; one might predict additional difficulties in children who have never acquired such abilities. Furthermore, whether the mechanisms responsible for visual agnosia following a cortical lesion in early childhood or in adulthood are identical is unclear, given the complex dynamics of developmental processes in the child (see below).

Whatever the diagnostic label of our patients, the interpretation of what appears to be their common ‘core deficit’ in neuroanatomical and neurophysiological terms can be grounded in recent findings on the functional organization of the adult visual system. Neurons responding appropriately for being involved in figure-ground segregation were recorded in V1 of the monkey (Lamme, 1995; Nothdurft et al., 1999). PET studies reported an increased activity of the primary and secondary visual areas during a figure-ground segregation task based on texture, rather similar to our rectangle orientation task (Gulyas et al., 1998). The involvement of primary visual areas in figure-ground segregation is evident from a recent fMRI study by Skiera et al. (2000), who revealed cortical activation of V1 to motion-, color-, and luminance-

defined checkerboards compared with control stimuli without boundaries.

Other areas are also activated in response to motion, color, or texture cues (Gulyas et al., 1994; Skiera et al., 2000; Kastner et al., 2000). In particular, motion can be processed, presumably in area V5 independent of the integrity of V1 (Barbour et al., 1993; Ffychte et al., 1996). This observation could explain the preserved perception of moving stimuli in both patients. The deficits in figure perception and figure-background segregation based on textural cues that we found in our patients support the hypothesis that areas 17 (and possibly 18) are crucially involved in figure perception and in figure-background segregation based on textural cues.

There are at least two plausible and non-mutually exclusive neuroanatomical/neurophysiological substrates for figure perception and figure-background segregation:

- i) One substrate consists of the feedback projections from higher-order to lower-order visual areas, in particular V4 (Lamme, 1995; Nothdurft et al., 1999; Kastner et al., 2000). Presumably these projections contribute to creating neuronal assemblies in lower-order visual areas by transmitting perceptual templates generated by experience-dependent processes in specialized signal-analyzing neurons in higher-order areas.
- ii) The second is the network of horizontal connections in area 17, particularly those between cortical columns sensitive to the same stimulus orientation (Gilbert, 1992; 1998 for review). These connections conform to Gestalt principles of collinearity (Bosking et al., 1997; Schmidt et al., 1997) and are involved in establishing coactive neuronal assemblies (discussed in Brosch et al., 1997; Roefelsma & Singer, 1998). Such assemblies include neurons in the two hemispheres connected by the corpus callosum (Engel et al., 1991; Munk et al., 1995; Novak et al., 1995). The formation of coactive inter-

hemispheric assemblies in both animals and humans can be detected as an increased inter-hemispheric coherence within the beta-gamma range during visual stimulation (Kiper et al., 1999; Knyazeva et al., 1999). This observation motivated the analysis of visual stimulus-induced changes in interhemispheric coherence in MS and FJ (Knyazeva et al., 2002).

Visual agnosia in children

Reports of visual agnosia in children are sparse, although the issue is of both theoretical and practical interest. Indeed, one might expect that the consequences of a lesion affecting the visual areas in a child would be different from those of a similar lesion in an adult and hence, should result in different deficits. The latter appears not to be true. Young and Ellis (1989) described a child who had suffered from meningococcal meningitis at 14 mo of age and showed prosopagnosia and agnosia, concluding that her deficits were similar to those of an adult. Ariel and Sadeh (1996) reported the case of a child with high IQ, who had intact basic visual skills, could read, and performed fairly well on a number of visual perceptual tests, albeit slowly. The child, however, had difficulties in integrating parts of an object into a whole, in recognizing objects from photographs, and was seriously impaired in recognizing objects from line drawings when these were overlapping or discontinuous. The child also had prosopagnosia. Instead, his visual memory was normal. Unfortunately, although the deficits appeared to be congenital, information on the nature or the location of the possible lesion is lacking. We also have no information on his visual acuity and do not know whether his visual field is normal.

Jambaqué et al. (1998) reported the case of a female child with congenital epilepsy originating in the right calcarine region who underwent right occipital lobectomy at the age of 7 y. Left hemi-

anopsia was noticed in the first year of life. Despite the lateralised nature of the lesion, the child had "erratic gaze, collided with objects and was unable to recognize people", at least as since the age of 4 y. Her IQ was low, possibly associated with deficits in the left frontal lobe. At 13 y of age, she "could recognize letters, digits and simple geometrical shapes such as triangles but had difficulties copying geometrical shapes of two elements—for example a square in a circle", and face discrimination was also impaired. "Impairment of object recognition was more evident with overlapping figures and when asked to reconstruct perceptively degraded objects." A further case of visual apperceptive agnosia in a child with congenital epilepsy involving the occipital cortex and no apparent lesions is currently under study (Deonna et al., unpublished). In conclusion, the studies mentioned above and the cases reported here indicate that the 'core deficit' of apperceptive agnosia (above) can be identified in children with congenital visual defect, and this despite the presumptive plasticity of the developing brain. It seems impossible to conclude from the published cases whether the agnosia is more severe after comparable lesions in adults or in children. The difficulties stem from the difference in the location and nature of the lesions, as well as in the types of tests used, most of which, in addition, do not lend themselves to quantification.

The cases reported here shed some new light on the issue of child agnosia, in relation to developmental brain plasticity (discussed in Knyazeva et al., 2002). The results of our study of MS and FJ indicate that their current visual impairment is the combined consequence of the loss of two components of visual perception, one that underwent minor or no compensation with age, and the other that did, at least in MS.

In MS, the deficit in contrast sensitivity remained almost stable for more than 4 y. It is tempting to ascribe this deficit to the probable

partial degeneration of ganglion cells that follows the cortical lesion, as described in animals (see for example, Cowey et al., 1982; Kisvarday et al., 1991). That a similar degeneration occurred in MS is suggested by the partial atrophy of the optic nerve, revealed by ophthalmological examination. Similar atrophy of the optic nerve in cases of early lesions of the visual cortex, and/or occipital periventricular leukomalacia has been reported before (Jacobson et al., 1997).

In contrast, the analysis of visual functions that are dependent on cortical mechanisms provides a striking example of the visual system's adaptive developmental plasticity. At the age of 4 y, MS had severe deficits in Vernier acuity and was unable to achieve simple figure-background segregation. Within 1 y, her performance in the Vernier task had improved by a factor of 2, above that which could be expected from normal maturation (Carkeet et al., 1997). Even more marked was her recovery in the figure-ground segregation based on textural features, which improved by a factor of 100 within 4 y. This improvement in her psychophysical performances was paralleled by changes in her daily visual behavior, as related by her schoolteachers and vision therapist, and the quality of her spontaneous drawings. According to these sources, MS started to rely more and more on visual information to guide her behavior. We also assume, on the basis of anamnestic information, that FJ also partially recovered vision during his early childhood, in particular during his second year of age. Clearly, however, the functional recovery in FJ was less important than that of MS because even despite his older age, he is much more severely impaired than MS.

ACKNOWLEDGMENTS

This work was supported by a Swiss National Science Foundation grant PNR38: n 4038-043990/1 and a Swedish Medical Research Council grant n

12594. We would like to thank Dr. C.A. Hiroz for providing us with the perimetry results and Prof. P.A. Despland for allowing us to perform EEG recordings in his department. Special thanks go to Prof. C. Rivaz, who allowed us to perform the psychophysical experiments in the Institute for Research in Ophthalmology (IRO), Sion, Switzerland, and to Mme. Matthis for her constant help.

REFERENCES

- Allard T, Clark SA, Jenkins WM, Merzenich MM. 1991. Reorganization of somatosensory area 3b representations in adult owl monkeys after digital syndactyly. *J Neurophysiol* 66: 1048–1058.
- Ariel R, Sadeh M. 1996. Congenital visual agnosia and prosopagnosia in a child: a case report. *Cortex* 32: 221–240.
- Barbour L, Watson JD, Frackowiack RS, Zeki S. 1993. Conscious visual perception without V1. *Brain* 116: 1971–1982.
- Benton AL. 1965. *Test de rétention visuelle* (deuxième édition française). Paris: Les Editions du Centre de Psychologie Appliquée.
- Bosking WH, Zhang Y, Schofield B, Fitzpatrick D. 1997. Orientation selectivity and the arrangement of horizontal connections in tree shrew striate cortex. *J. Neurosci* 17: 2112–2127.
- Bradley A, Freeman RD. 1982. Contrast sensitivity in children. *Vision Res* 22: 953–959.
- Bressoud R, Innocenti GM. 1999. Typology, early differentiation, and exuberant growth of a set of cortical axons. *J Comp Neurol* 406: 87–108.
- Brosch M, Bauer R, Eckhorn R. 1997. Stimulus-dependent modulation of correlated high-frequency oscillations in cat visual cortex. *Cereb Cortex* 7: 70–76.
- Butter CM and Trobe JD. 1994. Integrative agnosia following progressive multifocal leucoencephalopathy. *Cortex* 30: 145–158.
- Carkeet A, Levi DM, Manny RE. 1997. Development of Vernier acuity in childhood. *Optom Vis Sci* 74: 741–750.
- Clarke S, Walsh V, Schopping A, Assal G, Cowey A. 1998. Colour constancy impairments in patients with lesions of the prestriate cortex. *Exp Brain Res* 123: 154–158.
- Cowey A. 1982. Sensory and non-sensory visual disorders in man and monkey. *Philos T Roy Soc B* 298: 3–13.
- Cowey A, Henken DB, Perry VH. 1982. Effects on visual acuity of neonatal or adult tectal ablation in rats. *Exp Brain Res* 48: 149–152.
- Darian-Smith C, Gilbert CD. 1994. Axonal sprouting accompanies functional reorganization in adult cat striate cortex. *Nature* 368: 737–740.
- De Renzi E and Lucchinelli F. 1993. The fuzzy boundaries of apperceptive agnosia. *Cortex* 29: 187–215.
- Engel AK, König P, Kreiter AK, Singer W. 1991. Interhemispheric synchronization of oscillatory neuronal responses in cat visual cortex. *Science* 252: 1177–1179.
- Farah MJ. 1990. *Visual agnosia. Disorders of object recognition and what they tell us about normal vision*. Cambridge, Massachusetts, USA: MIT Press.
- Ffychte DH, Guy CN, Zeki S. 1996. Motion specific responses from a blind hemifield. *Brain* 119: 1971–1982.
- Finney DJ. 1971. *Probit Analysis*. 3rd ed. Cambridge, UK: Cambridge University Press.
- Frost DO. 1986. Development of anomalous retinal projections to non visual thalamic nuclei in Syrian hamsters: a quantitative study. *J Comp Neurol* 252: 95–105.
- Gardner MF. 1982. *Test of Visual-Perceptual Skills (non-motor)*. Burlingame, California, USA: Psychological and Educational Publications.
- Gauthier L, Dehaut F, Joannette Y. The Bell's Test: A quantitative and qualitative test for visual neglect. *Int J Clin Neuropsych* 1989; 11: 49–54.
- Gilbert CD. 1992. Horizontal integration and cortical dynamics. *Neuron* 9: 1–13.
- Gilbert CD. 1998. Adult cortical dynamics. *Physiol Rev* 78: 467–485.
- Groeneweld M, Pohl KRE, Espezel H., Jan JE. 1994. The septum pellucidum and spatial ability of children with optic nerve hypoplasia. *Dev Med Child Neurol* 36: 191–197.
- Grossman M, Galetta S, D'Esposito M. 1997. Object recognition difficulty in visual apperceptive agnosia. *Brain Cognition* 33: 306–342.
- Grüsser OJ, Landis T. 1991. *Visual agnosias and other disturbances of visual perception and cognition*. London, UK: Macmillan Press.
- Gulyás B, Cowey A, Heywood CA, Popplewell C, Roland PE. 1998. Visual form discrimination from

- texture cues: A PET study. *Hum Brain Mapp* 6: 115–127.
- Gulyás B, Heywood CA, Popplewell C, Roland PE, Cowley A. 1994. Visual form discrimination from color or motion cues: Functional anatomy by positron emission tomography. *Proc Natl Acad Sci USA* 91: 9965–9969.
- Hasnain MK, Fox PT, Woldorff M G. 2001. Structure-function spatial covariance in the human visual cortex. *Cereb Cortex* 11: 702–716.
- Hooper HE. 1983. *Visual Organization Test (VOT)*. Los Angeles, California, USA: Western Psychological Services. START
- Humphreys GW, Riddoch MJ. 1987. To see but not to see. A case study of visual agnosia. London, Lawrence Erlbaum Associates.
- Innocenti GM. 1991. The development of projections from cerebral cortex. *Progr Sens Physiol* 12: 65–114.
- Innocenti GM. 1995. Exuberant development of connections, and its possible permissive role in cortical evolution. *Trends Neurosci* 18: 397–402.
- Innocenti GM, Kiper DC, Knyazeva MG, Deonna TW. 1999. Nature and limits of cortical developmental plasticity in a child. *J Restorative Neurol Neurosci* 15: 219–227.
- Jambaqué I, Mottron L, Ponsot G, Chiron C. 1998. Autism and visual agnosia in a child with right occipital lobectomy. *J Neurol Neurosurg Psychiatry* 65: 555–560.
- Jacobson L, Hellström A, Flodmark O. 1997. Large cups in normal-sized optic discs. A variant of optic nerve hypoplasia in children with periventricular leukomalacia. *Arch Ophthalmol* 115: 1263–1269.
- Kartsounis LD, Warrington EK. 1991. Failure of object recognition due to a breakdown of figure-ground discrimination in a patient with normal acuity. *Neuropsychologia* 29: 969–980.
- Kastner S, De Weerd P, Ungerleider LG. 2000. Texture segregation in the human visual cortex: A functional MRI study. *J Neurophysiol* 83: 2453–2457.
- Kaufman AS, Kaufman NL. 1993. *Batterie pour l'examen psychologique de l'enfant*. Paris: Les Editions du Centre de Psychologie Appliquée.
- Kiper DC, Knyazeva MG, Tettoni L, Innocenti GM. 1999. Visual-stimulus-dependent changes in interhemispheric EEG coherence in ferrets. *J Neurophysiol* 82: 3082–3094.
- Kiper DC, Knyazeva MG, Maeder M, Maeder P, Despland PA, Innocenti GM. 1998. Central adaptations and spared visual capacities following cortical damage in children. *Europ J Neurosci Suppl* 10: 236.
- Kisvarday ZF, Cowey A, Stoeri P, Somogyi P. 1991. Direct and indirect retinal input into degenerated dorsal lateral geniculate nucleus after striate cortical removal in monkey: implications for residual vision. *Exp Brain Res* 86: 271–292.
- Knyazeva MG, Deonna T, Innocenti GM. 2000. Functional interhemispheric connectivity following early cortical pathology. *Europ J Neurosci Suppl* 12: 284.
- Knyazeva MG, Kiper DC, Vildavski VY, Despland PA, Maeder-Ingvar M, Innocenti GM. 1999. Visual-stimulus-dependent changes in interhemispheric EEG coherence in humans. *J Neurophysiol* 82: 3095–3107.
- Knyazeva MG, Maeder P, D.C. Kiper DC, Deonna T, and Innocenti GM. 2002. Vision after *early-onset* lesions of the occipital cortex: ii) Physiological studies. *Neural Plasticity* 9: 27–40.
- Lamme VAF. 1995. The neurophysiology of figure-ground segregation in primary visual cortex. *J Neurosci* 15: 1605–1615.
- Lobrot, M. 1967. Batterie d'épreuves pour mesurer la lecture et l'orthographe. Bureau d'Etudes et de Recherches de Beaumont-sur-Oise.
- Marcar VL, Zihl J, Cowey A. 1997. Comparing the visual deficits of a motion blind patient with the visual deficits of monkeys with area MT removed. *Neuropsychologia* 35: 1459–1465.
- Merzenich MM, Nelson RJ, Stryker MP, Cynader MS, Schoppmann A, Zook JM. 1984. Somatosensory cortical map changes following digit amputation in adult monkeys. *J Comp Neurol* 224: 591–605.
- Métin C, Frost DO. 1989. Visual responses of neurons in somatosensory cortex of hamsters with experimentally induced retinal projections to somatosensory thalamus. *P Natl Acad Sci USA* 86: 357–361.
- Milner AD, Perrett DI, Johnston RS, Benson PJ, Jordan TR, Heeley DW, Bettucci D, Mortara F, Mutani R, Terazzi E, Davidson LW. 1991. Perception and action in visual form agnosia. *Brain* 114: 405–428.
- Mizuno M, Sartori G, Liccione D, Battelli L, Campo P. 1996. Progressive visual agnosia with posterior

- cortical atrophy. *Clin Neurol Neurosurg* 98: 176–178.
- Mousty P, Leybaert J., Alegria J, Content A, Morais J. 1994. BELEC: Une batterie d'évaluation du langage écrit et de ses troubles. In: Grégoire J, Piérart B, eds, *Evaluer les troubles de la lecture*. Bruxelles, Belgium: DeBoeck.
- Moore T, Rodman HR, Repp AB, Gross CG, Mezrich RS. 1996. Greater residual vision in monkeys after striate cortex damage in infancy. *J Neurophysiol* 76: 3928–3933.
- Munk MHJ, Nowak LG, Nelson JJ, Bullier J. 1995. Structural basis of cortical synchronization. II. Effects of cortical lesions. *J Neurophysiol* 74: 2401–2414.
- Nothdurft HC, Gallant JL, Van Essen DC. 1999. Response modulation by texture surround in primate area V1: Correlates of "popout" under anesthesia. *Visual Neurosci* 16: 15–34.
- Nowak LG, Munk MHJ, Nelson JJ, James AC, Bullier J. 1995. Structural basis of cortical synchronization. I. Three types of interhemispheric coupling. *J Neurophysiol* 74: 2379–2400.
- Payne BR. 1999. System-wide repercussions and adaptive plasticity: the sequelae of immature visual cortex damage. *Rest Neurol Neurosci* 15: 81–106.
- Payne BR, Cornwell P. 1994. System-wide repercussions of damage to the immature visual cortex. *Trends Neurosci* 17: 126–130.
- Payne BR, Lomber SG, MacNeil MA, Cornwell P. 1996. Evidence for greater sight in blindsight following damage of primary visual cortex early in life. *Neuropsychologia* 34: 741–774.
- Perry VH, Cowey A. 1982. A sensitive period for ganglion cell degeneration and the formation of aberrant retino-fugal connections following tectal lesions in rats. *Neuroscience* 7: 583–594.
- Ptito M, Daylby M, Gjedde A. 1999. Visual field recovery in a patient with bilateral occipital lobe damage. *Acta Neurol Scand* 99: 252–254.
- Riddoch MJ, Humphreys GW. 1993. *Birmingham Object Recognition Battery*. Hove: Lawrence Erlbaum Associates.
- Roelfsema PR, Singer W. 1998. Detecting connectedness. *Cereb Cortex*; 8: 385–396.
- Recanzone GH, Schreiner CE, Merzenich MM. 1993. Plasticity in the frequency representation of primary auditory cortex following discrimination training in adult owl monkeys. *J Neurosci* 13: 87–103.
- Safran AB, Landis T. 1999. From cortical plasticity to unawareness of visual field defects. *J Neuroophthalmol* 19: 84–88.
- Santucci H, Pêcheux MG. 1967. *Test de Bender - Adaptation HHR*. Paris: Les Editions du Centre de Psychologie Appliquée.
- Schmidt KE, Goebel R, Löwel S, Singer W. 1997. The perceptual grouping criterion of colinearity is reflected by anisotropies of connections in the primary visual cortex. *Eur.J.Neurosci* 9:1083–1089.
- Schneider GE. 1979. Is it really better to have your brain lesion early? A revision of the "Kennard principle". *Neuropsychologia* 17: 557–583.
- Schneider GE. 1981. Early lesions and abnormal neuronal connections. *Trends Neurosci* 4: 187–192.
- Signoret JL. 1991. *Batterie d'efficience mnésique BEM 144*: Paris: Elsevier.
- Skiera G, Petersen D, Skalej M, Fahle M. 2000. Correlates of figure-ground segregation in fMRI. *Vision Res* 40: 2047–2056.
- Sur M, Pallas SL, Roe AW. 1990. Cross-modal plasticity in cortical development: differentiation and specification of sensory neocortex. *Trends Neurosci* 13: 227–233.
- Vecera S P, Gilds KS. 1998. What processing is impaired in apperceptive agnosia? Evidence from normal subjects. *J Cogn Neurosci* 10: 568–580.
- Warrington E, James M. 1988. Visual apperceptive agnosia: a clinico-anatomical study of three cases. *Cortex* 24: 13–32.
- Wechsler D. 1989. *Echelle d'intelligence de Wechsler pour adultes, forme révisée*. Paris: Les Editions du Centre de Psychologie Appliquée.
- Wechsler D. 1996. *Echelle d'intelligence de Wechsler pour enfants - Troisième édition*. Paris: Les Editions du Centre de Psychologie Appliquée.
- Weiskrantz, L. 1990. *Blindsight: A case study and implications*. Oxford Univ. Press.
- Williams RA, Boothe RG, Kiorpes L, Teller DY. 1981. Oblique effects in normally reared monkeys (*Macaca Nemestrina*): Meridional variations in contrast sensitivity measured with operant techniques. *Vision Res* 21: 1253–1266.
- Young AW, Ellis HD. 1989. Childhood prosopagnosia. *Brain Cognition* 9: 16–47.

Zeki S. 1993. A vision of the brain. Cambridge, MA: Blackwell Scientific Publications.

Zilles K, Clarke S. 1997. Architecture, connectivity, and transmitter receptors of human extrastriate visual

cortex. Comparison with nonhuman primates. In: Rockland KS, Kaas JH, and Peters A, eds, Cerebral Cortex Vol. 12, Extrastriate Cortex in Primate; 673–742. New York, NY, USA: Plenum Press.